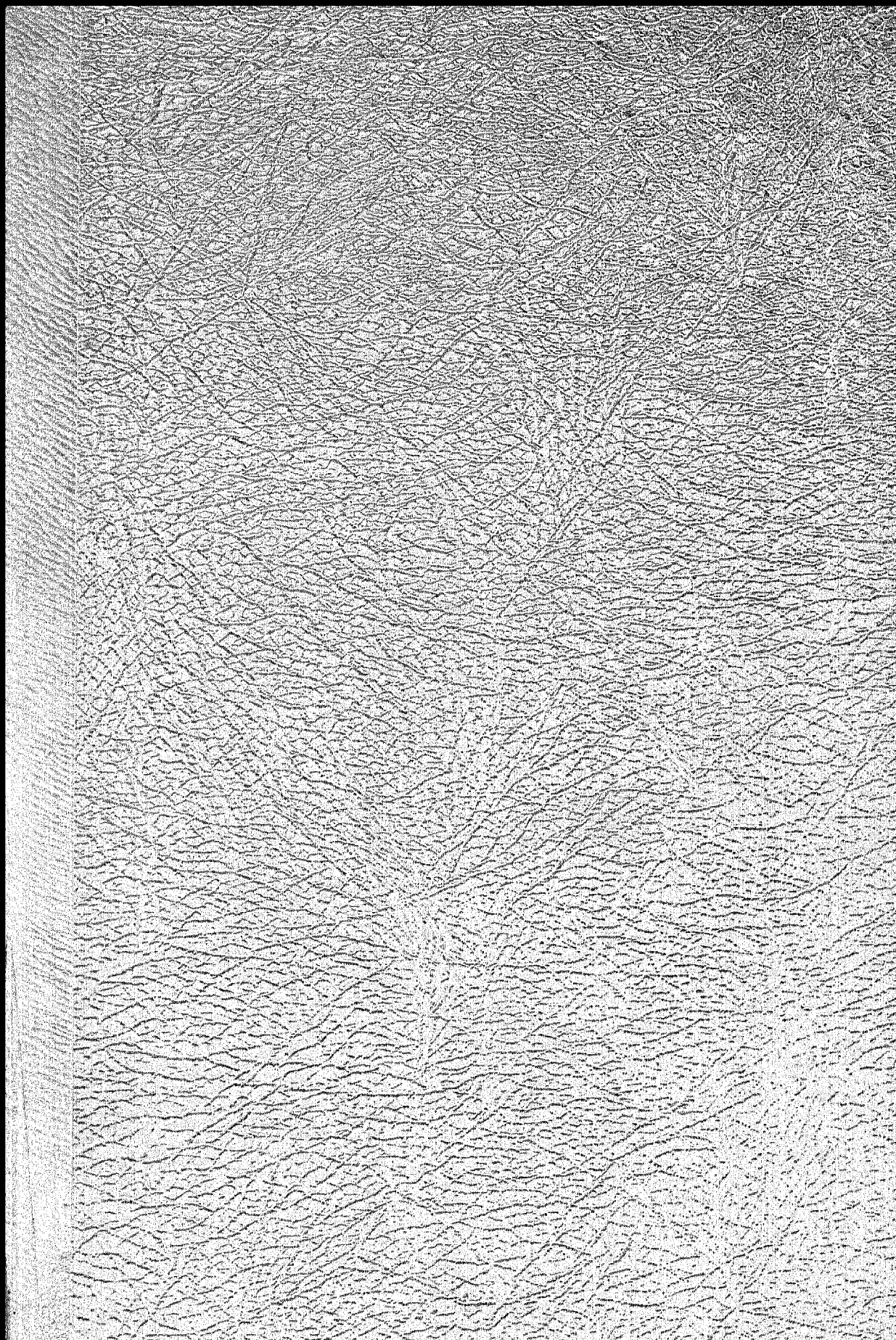

**CORRECTION OF NASAL DEFORMITIES  
IN CASES OF UNILATERAL CLEFT LIP**

THESIS

Submitted for Partial Fulfillment of M.Sc. Degree  
In  
General Surgery

By

**Moustafa Badr Ebraheium**  
M.B.B.Ch.

Supervised By

***Dr. Magdy Mohamed El-Barbary***

Professor of Pediatric Surgery  
Faculty of Medicine – Cairo University

***Dr. Nasser Ali Abdel Aal***

Assistant Professor of Pediatric Surgery  
Faculty of Medicine – Cairo University

***Dr. Omar Mohamed Mansour***

Lecturer of Pediatric Surgery  
Faculty of Medicine – Cairo University

Faculty of Medicine  
Cairo University

**2001**

محضر

اجتماع لجنة الحكم على الرسالة المقدمة من  
الطبيب / مصطفى عبد إبراهيم  
توظيفة للحصول على درجة الماجستير / الدكتورة  
في

تحت عنوان : باللغة الانجليزية : Correction of nasal deformities in cases of Unilateral cleft lip

: باللغة العربية : اصحاح عيوب الانف في حالات تشوهات الشفة العليا

بناء على موافقة الجامعة بتاريخ ١٤٠٠ / ١٨ - ١٢ تم تشكيل لجنة الفحص والمناقشة للرسالة المذكورة أعلاه على النحو التالي :-

- (١) د. محمد محمد البدر عن المشرفين
- (٢) د. جمال زهران متحن داخلي
- (٣) د. نيل المحلوي متحن خارجي

بعد فحص الرسالة بواسطة كل عضو منفردا وكتابة تقارير منفردة لكل منهم لعنقدت اللجنة مجتمعة فسي يوم الثلاثاء بتاريخ ١٧ / ٤ / ١٩٠٠ بقسم الانف والاذن مدبر الطبيب ارتداد بكلية الطب - جامعة القاهرة وذلك لمناقشة الطالب في جلسة علنية في موضوع الرسالة والنتائج التي توصل اليها وكذلك الاسس العلمية التي قام عليها البحث .

قرار اللجنة : وافقت اللجنة بالإجماع على قبول الرسالة  
المقدمة وتوظيفة الدكتور محمد إبراهيم

تفويضات أعضاء اللجنة :-

المتحن الخارجي  
د. محمد محمد البدر

المتحن الداخلي  
د. جمال زهران

المشرف المتحن  
د. محمد محمد البدر  
(صام)

# ***Abstract***

Twenty patients with unilateral cleft lip nasal deformities were operated from October 1999 to October 2000.

Five patients were operated primary at the time of lip repair with their age ranged between 6 to 12 months, 15 patients were operated secondary after lip repair had done, with their age ranged between 2 to 12 years. Compared operative procedures depending on the severity of the cleft lip nasal deformity, were the following:

- (1) Bilateral reverse-u rim incision with suture suspension of the lower cartilages combined with Millard's rotation advancement repair of the cleft lip in primary cases.
- (2) Bilateral reverse-u incision connected with transcolumellar v-shaped incision with :
  - a) Suture suspension of the alar cartilages.
  - b) Z-plasty at the lateral end of incision for alar web deformity.
  - c) v-y plasty for short columella.

Most of the patients were satisfied with their surgical results.

Language : English.

## **Key Words :**

Cleft lip – nasal deformity.

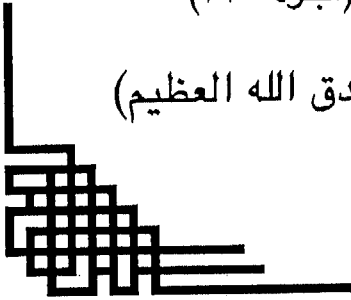


بِسْمِ اللَّهِ الرَّحْمَنِ الرَّحِيمِ

« قالوا سبحانك لا علم لنا إلا ما علمتنا

إنك أنت العزيز الحكيم » (البقرة - ٣٢)

(صدق الله العظيم)



# **ACKNOWLEDGMENT**

Thanks to **ALLAH** first and foremost. I feel always indebted to **ALLAH**, the most kind and he most merciful.

No words could express my feeling, gratitude, respect and lowly to eminent **Prof. Dr. Magdy El-Barbary**, Professor of Pediatric Surgery, Faculty of Medicine, Cairo University for his kind support during the period of my training in the department of pediatric surgery and for all his endless support, guidance and assistance.

I would like to express my utmost thanks and great appreciation to **Dr. Nasser Abdel Aal**, Assistant Professor of Pediatric Surgery, Faculty of Medicine, Cairo University for his very valuable help, precious advice, constructive guidance his expert advice bounding patience and construct support were on inspiration to me through at the completion of this work.

I also wish to express my sincere gratitude and thanks to **Dr. Omar Mansour**, Lecturer of Pediatric Surgery, Cairo University, for his valuable guidance and expert advice. His great kindness, help and cooperation till completion of this work. Not only he suggested the idea of this thesis but also supervised every step and worked hard to make it reach its final form.

Special thanks for **All Staff and Doctors of the Pediatric Surgical Department**, for their support in the completion of this work.

# *CONTENTS*

	<b>Page</b>
<b>Introduction</b>	<b>1</b>
<b>Review Of Literature</b>	
Embryology	2
Anatomy	8
Pathological Anatomy	26
Timing of Correction of Nasal Deformity	35
Surgical Correction of Nasal Deformity	43
<b>Patients and Methods</b>	<b>97</b>
<b>Results</b>	<b>104</b>
<b>Discussion</b>	<b>117</b>
<b>Conclusion</b>	<b>122</b>
<b>Summary</b>	<b>123</b>
<b>References</b>	<b>124</b>
<b>Arabic Summary</b>	

## *List of Figures*

Figures	Page
<b>Fig. (1) : Development of human face</b>	6,7
<b>Fig. (2) : Osteocartilaginous framework of the nose</b>	10
<b>Fig. (3) : Surface anatomy of the nose</b>	10
<b>Fig. (4) : alar cartilage</b>	13
<b>Fig. (5) : Segmental anatomy of the alar cartilage</b>	15
<b>Fig. (6) : Alar cartilage and its accessory cartilages</b>	15
<b>Fig. (7) : Soft triangle of the nose</b>	18
<b>Fig. (8) : The weak triangle and the suspensory ligament of the nose</b>	18
<b>Fig. (9) : The muscles of the nose</b>	25
<b>Fig. (10) : Deformities of nasal tip in the cleft lip nose</b>	30
<b>Fig. (11) : The tilted tripod</b>	31
<b>Fig. (12) : Muscular repair with mobilization and suturing to midline nasalis, levators and orbicularis musculature</b>	47
<b>Fig. (13) : Primary nasal reconstruction with transfixation sutures through and through internal nasal valve</b>	49
<b>Fig. (14) : Modification of millard's rotation advancement method and harashina's Open rhinoplasty</b>	53
<b>Fig. (15) : Mucoperiosteal undermining on the medial wall of maxilla</b>	53
<b>Fig. (16) : Planning lines howing modification of millard's rotation advancement method and harashina's Open rhinoplasty</b>	54
<b>Fig. (17) : Methodology of orbicularis muscle repair</b>	54
<b>Fig. (18) : The medial crura, domes and cranial edge of lateral crura are suturing using 4/0 vicryl</b>	55
<b>Fig. (19) : Suture is passed from the deep dermis just above the nasal tip.</b>	55
<b>Fig. (20) : Suturing of nostril rims is completed followed by tailoring of the nostril still and nostril base</b>	55
<b>Fig. (21) : Presurgical orthodontics align. The alveolar segment</b>	59
<b>Fig. (22) : Presurgical orthodontics, gingivo periosteoplasty and lip adhesion by aligning the alveolar segment.</b>	59
<b>Fig. (23) : Method of exposing and correction of the lower lateral cartilage deformity</b>	63
<b>Fig. (24) : Selection of methods for suspension of the deformed lower lateral cartilage</b>	66
<b>Fig. (25) : Cleft lip nasal retractor</b>	68
<b>Fig. (26) : Cleft lip nasal retractor passed through the incision</b>	68
<b>Fig. (27) : Open-reverse – U incision technique of Harashina 1990</b>	70
<b>Fig. (28) : The nose of patient with unilateral cleft lip and intranasal rim incision of Koh, K.S. and Eom J.S., 1999</b>	73



## *List of Tables*

<b>Tables</b>	<b>Page</b>
<b>Table (1) : Distribution of the studied cases according to the age</b>	<b>104</b>
<b>Table (2) : Distribution of the studied cases according to sex</b>	<b>105</b>
<b>Table (3) : Distribution of the studied cases according to time of lip repair</b>	<b>105</b>
<b>Table (4) : Distribution of the studied cases according to nasal deformity</b>	<b>106</b>
<b>Table (5) : Scoring system for assessment of the results</b>	<b>107</b>
<b>Table (6) : Distribution of the studied cases according to the result of operative technique</b>	<b>108</b>
<b>Table (7) : Distribution of the studied cases according to postoperative morbidity</b>	<b>109</b>
<b>Table (8) : Distribution of the studied cases according to overall results</b>	<b>110</b>
	<b>111</b>

## *List of Plates*

Plate	Page
Plate (1) : Preoperative view of male child 6 months	111
Plate (2) : Intraoperative view of the same child	111
Plate (3) : Postoperative view of the same child one week postoperative	112
Plate (4) : Preoperative view of a female child 3 years with buckling and bifidity of the alar cartilage.	112
Plate (5) : Intraoperative view of the same child.	113
Plate (6) : Postoperative view of the same child one week Postoperatively.	113
Plate (7) : Preoperative view of a male child 8 years with repaired left unilateral cleft lip with secondary nasal deformity.	114
Plate (8) : Postoperative view of the same child one week postoperatively.	114
Plate (9) : Preoparetive view of a female child 12 years with Secondary unilateral cleft lip nasal deformity.	115
Plate (10) : Postoperative view of the same child one week postoperative.	115

***INTRODUCTION  
AND  
AIM OF THE WORK***

## **INTRODUCTION**

Patients born with cleft lip present with a variety of Nasal deformities this are either congenital or iatrogenic.

The management of cleft lip nasal deformities remains the most difficult, involved and challenging aspect of cleft lip surgery.

Corrections of nasal deformities involve solving many complex problems including malposition of exterior nose, deformity of nasal tip, deviation of the ala on the cleft side, septal deformity. The stigma of the patient with cleft is sustained mainly by the asymmetry of the nasal, entrances, many operations some of which cause extensive additional scarring have been suggested for removing this typical feature in patients with cleft (**Gubish W., 1998**).

No single procedure developed until now has given satisfactory results to provide an ideal surgical method for cleft lip nasal deformity corrections (**Mazzola R.F., 1996**).

The secondary corrective procedure focus mostly on skeletal support and lining distortion as well as rearrangement of lower lateral cartilages (**Salyer K.E., 1992**).

Controversy exists regarding the best time to perform the surgical correction of these deformities. When this is done sometime after cleft lip repair, open or external rhinoplasty is the best approach. It allows accurate repositioning and secure stabilization of key anatomical structures under direct vision (**Thomas C. and Mishra P., 2000**).

The aim of this work is to study the different methods of repair of unilateral cleft lip nasal defomities using the open structure rhinoplasty technique. Evaluation of the results will be clarified and discussed.

***REVIEW OF  
LITERATURE***

## **EMBRYOLOGY**

### **Early embryonic development :**

The cranial end of the human embryo undergoes precocious development beginning in the middle of the third week at which time the three germ layers in the cranial part of the embryo begin their specific development.

The three primary germ layers consist of ectoderm, mesoderm and endoderm serve as a basis for differentiation of the tissues and organs within the developing embryo.

The neural crest cells are unique in that, inspite of their ectodermal origin, they consist of pleopotential ectomesenchymal tissue comparable to the three primary germ layers.

Neural crest derivatives include connective tissue, muscle tissue, nervous tissue, endocrine tissue and pigment cells.

**Kissel and colleagues, (1981)** described a streaming of neural crest cells into the mesoderm of the early facial and frantonasal prominences and laterally into 1<sup>st</sup> and 2<sup>nd</sup> branchial arches which will become the maxilla and mandible. These neural crest cells are believed to be responsible for fusion of the facial prominence (Fig. 1a).

Early in the fourth week, the branchial arches begin to develop from the connective tissue and muscle elements of the neural crest.

The branchial arches are largely responsible for the formation of the face, neck, nasal cavities, mouth, larynx and pharynx.

The first branchial arch contributes to maxillary and mandibular prominences and anterior portion of the auricle.

The paired maxillary and mandibular prominences derived from the first arch form the lateral and caudal borders of the stomodeum (primitive mouth) respectively.

The frantonasal prominence, a central process formed by the proliferation of the mesenchyme ventral to the forebrain, forms the cranial boundary of the stomodeum.

These five prominences (two paired and one unpaired) bordering stomodeum are responsible for the development of adult facial features.

The quadrate cartilage within the maxillary prominence forms the incus and greater wing of sphenoid bone while the maxilla, zygoma and squamous portion of the temporal bone form from membranous ossification within the maxillary prominence.

Bilateral thickenings of the surface ectoderm called nasal placodes develop at the inferior aspect of the frantonasal prominence by the end of the fourth week (Fig. 1b).

With further elevation of the margin of the nasal placodes. The sides develop into medial and lateral nasal prominences respectively while the depressed central region of the placodes develops into the nasal pit.

The nasal pits initially in contact with the stomodeum are precursors of the nares.

The paired maxillary prominences continue to migrate medially also affecting medial migration of the medial and lateral nasal prominences.

Fusion of the medial nasal, lateral nasal and maxillary prominences produces continuity between the nose, the upper lip and palate.

Fusion of the medial nasal and maxillary prominences result in separation of the nasal pits from the stomodeum and subsequent separation of the oral and nasal cavities.

Merging of the medial nasal prominences forms the philtrum and Cupid's bow of the upper lip, the nasal tip, the premaxilla and primary palate and nasal septum.

The lateral nasal prominences form nasal alae.

The nasolacrimal groove develops as a furrow separating the lateral nasal prominence from the maxillary prominence, rods of epithelial cells sink into the subjacent mesenchyme to line this groove which extends from the medial aspect of the developing conjunctival sacs to the external nares (Fig. 1c).

The resultant nasolacrimal duct becomes patent only after birth.

Merging of the paired mandibular prominences produces the lower lip, lower jaw, lower cheek and chin regions of the face.

The maxillary prominence accounts for the major portion of the upper lip (excluding philtrum) and upper cheek regions.

The frontonasal prominence forms the forehead and nasal dorsum and the derivative of the medial and lateral nasal prominences previously discussed.

Unilateral cleft lip result from failure of fusion of the medial nasal prominence and maxillary prominence on one side.

Bilateral cleft lip result from failure of fusion of the merged medial nasal prominences with maxillary prominence on either sides.

### *Nasal cavities :*

During the six week of development, the nasal pits deepen as a result of formation of the medial and lateral nasal prominences eventually forming nasal sacs.



The nasal sacs are initially separated from the oral cavity by the oronasal membrane. Once this membrane ruptures, the oral and nasal cavities communicate via the primitive choanae (foramina).

These foramina initially lie behind the primary palate then shift posteriorly to the junction of the nasal cavity and pharynx after the formation of the secondary palate, the fusion of the lateral palatine processes and nasal septum are responsible for this final location of the choanae (Gosain K. and Moore O., 1997).

The cartilaginous framework of the nose is developing by the end of 10 week. Three paired condensations of mesenchyme in the medial and lateral nasal swelling initially are formed. The trabeculae cranii, in the primitive nasal system, the tectal condensations, located dorsally around the primitive nares, and paranasal condensation, located further posteriorly in the lateral nasal swelling. This cartilage model will ossify over the next 4 week, becoming the posterior septum, ethmoid complex, and nasal bone (Millard, 1976).

Postnasal growth and development is predictable and sporadic. The infantile nose is proportionally smaller and more broad with visible nares. Growth is very rapid initially and then slows in early childhood. Another burst occurs during the pubertal growth spurt, after which activity decline (Ortiz-Monastero and Olmedo, 1981).

Many factors influence postnatal development of the nose such as occlusion of teeth, tongue placement, facial musculature and development of the sinuses (Marsh, 1990).

Whether or not the nasal septum is the main determinant of postnatal development is debatable (Gross W. and Boyle R., 1993).

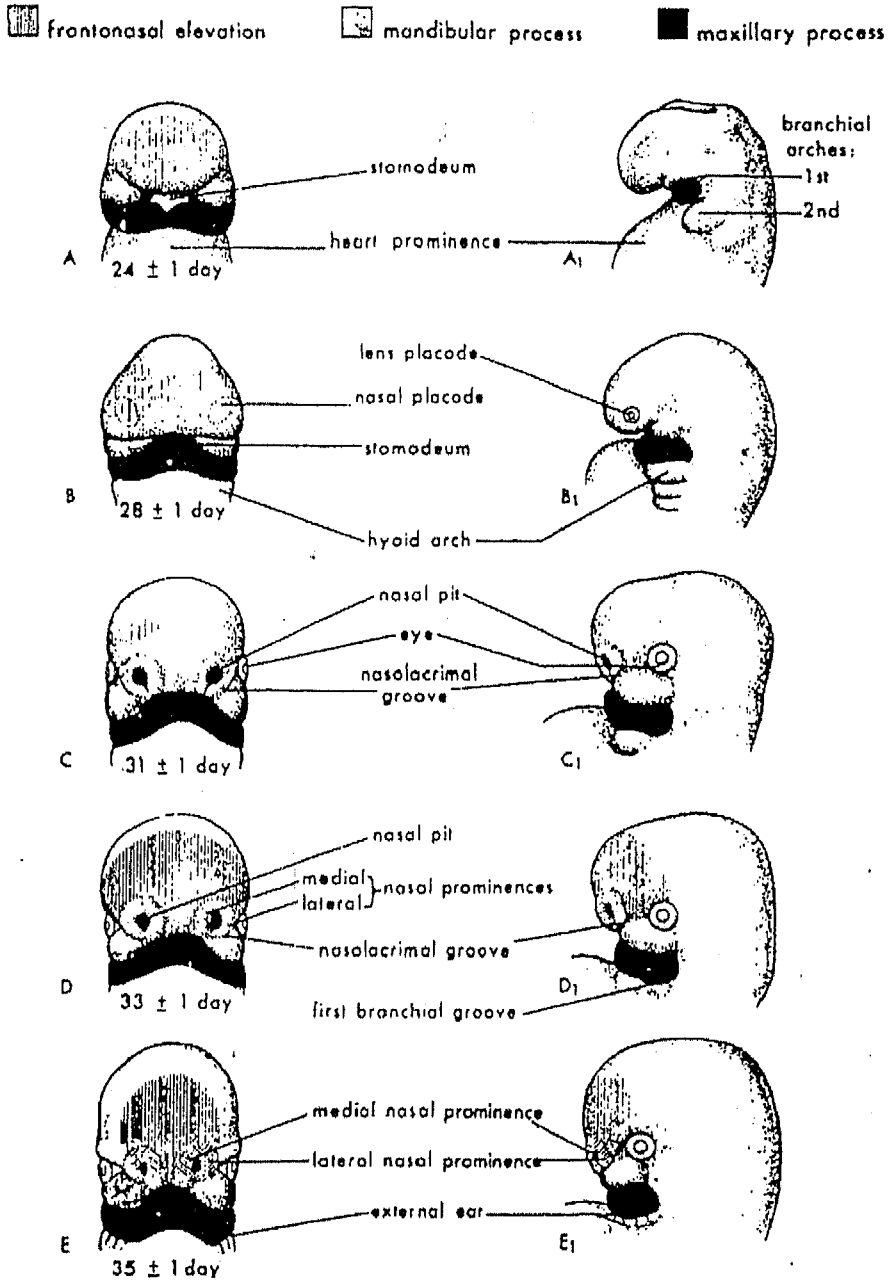


Fig. (1) : Diagram illustrating progressive stages in the development of the human face (Moore K.L., 1988)

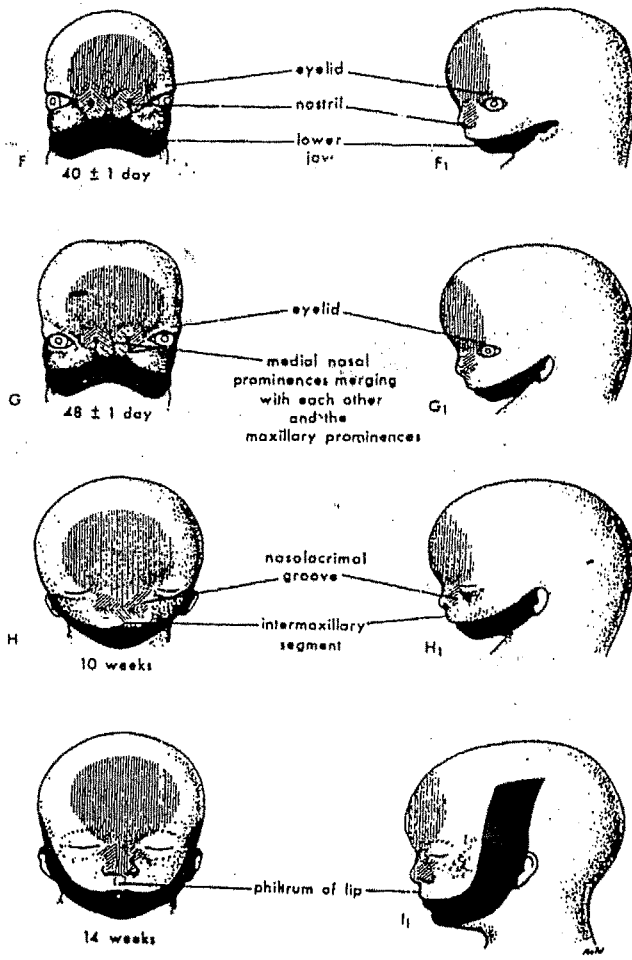


Fig. (1) (Cont.) : Diagram illustrating progressive stages in the development of the human face (Moore K.L., 1988)

## **ANATOMY OF THE NOSE**

The most prominent and characteristic features of the face is the nose. Its shape, which is both familial and individual, varies from Grecian to Aquiline.

The nose is shaped as a pyramid.

The nasal pyramid is an osteocartilaginous structure covered with soft tissues that include skin, subcutaneous tissue, muscle and epithelium.

- The nose can be divided into three components (Sheen, 1978).
- The bony vault (frontal processes of maxilla and nasal bones).
- Upper cartilaginous vault (upper lateral cartilages).
- Lower cartilaginous vault (medial and lateral crura, alae, alar lobules, nostril vestibules and stils, columella, and membranous septum) (Fig. 2).

### ***Covering soft tissues of nose :***

The skin of the nose varies from individual to individual in its oiliness, thickness and porosity. At the tip, the skin of the nose is tightly bound to the alar cartilage in contrast, the skin and musculature are loosely attached and mobile over the lateral cartilages and nasal bones.

The arteries and veins of nose are situated in the soft tissues.

### **Essential external landmarks of nose :**

- *The dorsum* or bridge of the nose is formed in part by the bony nose and in part by the cartilaginous nose (Fig. 3).

- *The nasofrontal angle* : is the area where the nose joins the forehead.
- *The tip of the nose* is formed by the junction of the two alae of the nose.
- *Columella* joins the tip of the nose to the upper lip and separates the two external nares.
- *The stills* are the slightly protuberant floor of the nostrils.
- The junction of the base of the columella with the upper lip defines the *nasolabial angle*.
- *Tip columellar angle* is formed by the intersection of the surface plane of the columella with that of the tip.

### **Bony structures of the nose :**

The bony portion of the nose is formed by the paired nasal bones. These are joined in the midline and are supported posteriorly by the nasal spine of the frontal bone and laterally by the frontal process of the maxilla.

The osseous lateral walls of the nose are formed by the nasal bones and frontal processes of the maxilla (bony vault).

The nasal bones are quadrangular, thick and narrow above. Thin and wide below. Their anterior surface is concave from above downward in upper portion convex from side to side. The thicker and stronger cephalic portion of the nasal bones is further reinforced by the nasal spine of the frontal bone.

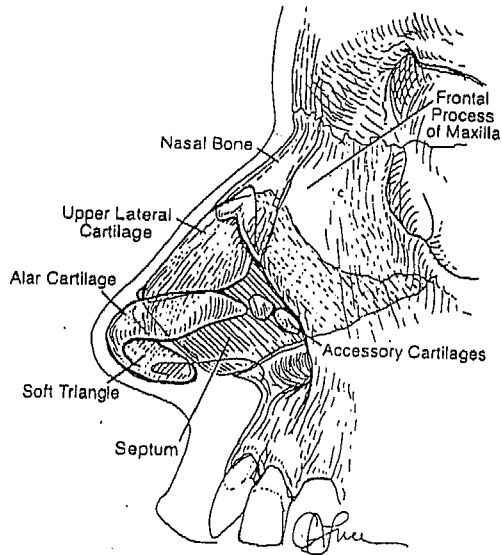


Fig. (2) : Osteocartilaginous framework of the nose (McCarthy and Wood Smith, 1990)

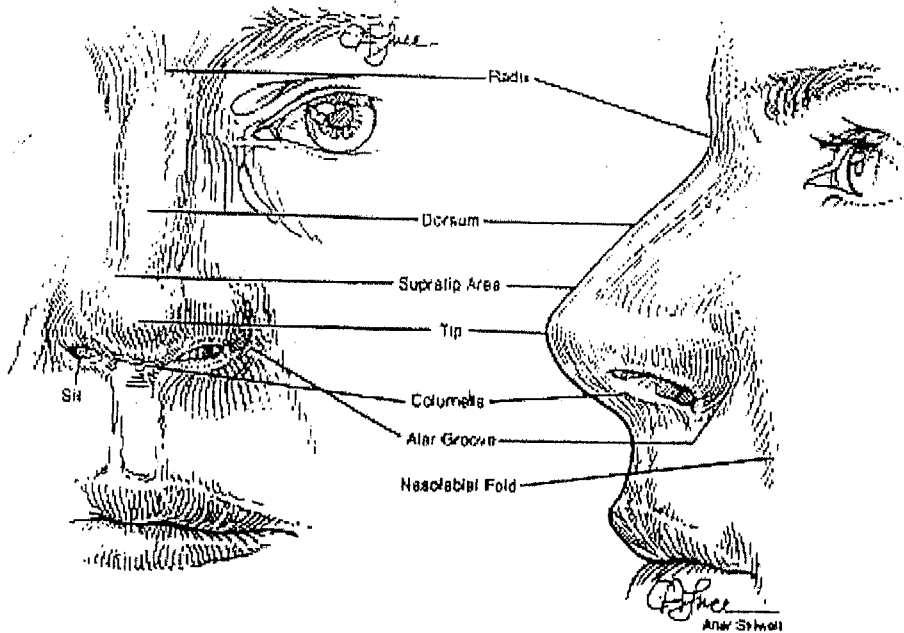


Fig. (3) : Surface anatomy of the nose (McCarthy and Wood Smith, 1990)

## **Cartilaginous structures of the nose :**

### *Lateral (upper lateral) cartilages :*

The lateral cartilages are paired structures, roughly triangular in shape, attached to the nasal bones and frontal processes of maxilla above and the septal cartilage in the midline.

The lower third of the lateral cartilages diverges from the septum, becomes mobile and constitutes the internal valve of the nose.

The lower portion of each lateral cartilage is thicker and turns on itself forming a cuff.

**Firmin and Lepesteur, (1977)** described small sesamoid cartilages that are present between the lateral cartilage and alar cartilage. The small sesamoid cartilages appear to act as roller bearings facilitating movement of the alar cartilage over the lateral cartilage.

The cartilages of the nose are subjected to movements by nasal musculature that play an important role in nasal physiology (**Zide, 1985**).

The alar cartilages are connected to the lateral cartilages by loose connective tissue that facilitates their cephalic displacement over the lateral cartilages.

The cartilaginous external nose is situated caudal and anterior to the piriform aperture.

The piriform aperture, the base of the nasal pyramid, is a pear shaped skeletal opening to the nasal fossae. It bounded above by the lower border of nasal bones and laterally by frontal processes of the maxilla, the thin, sharp margin of which extend downward, where they curve medially to join each other at the anterior nasal spine.

### **Alar (lower lateral) cartilages :**

The alar cartilages are paired structures that form the cartilaginous framework of the tip of the nose.

Each cartilage consists of two portions, a medial crus and lateral crus, which are joined at the most prominent point of the tip of the nose, the dome of the alar cartilage (Fig. 4).

The medial crura curve downward to form the skeletal framework of the columella. As they extend downward, they diverge at their lower end (the foot plates of the medial crura). The maximal divergence being reached at the widened base of the columella.

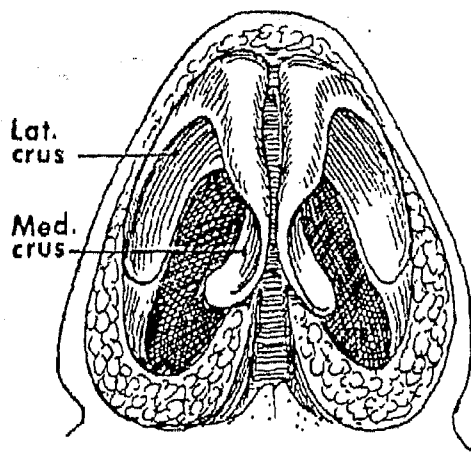
Each medial crus is intimately adherent to the skin of the columella. In dissected specimens, when viewed from their caudal aspect (the "worm's eye view"). The lateral crura and dome show a distinct downward curve of their caudal portions.

The caudal margin is lower than the dome and the more cephalic portion of the lateral crus. The size, shape and orientation of the alar cartilages, particularly the lateral crura, vary. The medial crura assume various curves and shapes (Natving et al., 1971).

The lateral portion of the lateral crus which occupies little more than the medial half of the ala, is joined to the edge of the piriform aperture by accessory and sesamoid cartilages.

Sheen H., (1991) in an anatomy laboratory dissect expose an entire alar cartilage, it was obvious between the medial and lateral crus there was a distinct segment that extended from medial genu to a lateral genu : A middle crus.





**Fig. (4) : The alar cartilages. Note the downward curve of the caudal portions and the flare of the medial crura (McCarthy and Wood Smith, 1990).**

With that observation, the surface anatomy of the nasal base finally made sense.

The base consisted of three definite units : The columella, the tip lobule and the alar rims.

The columellar lobular junction indicated the medial genu or the angulation between the medial genu and middle crura. This angle he defined as the angle of rotation (Fig. 5).

The height of lobule reflected the length of middle crura, and on front view the tip was defined by the distance between the lateral genu. This distance was determined by the angle of divergence or the relationship of middle crura to each other.

Keeping the relationship between the middle crura in mind, one can see that a broad tip is the manifestation of a wide angle of divergence, controversy, a narrow angle of divergence creates a pointed tip, lacking the attractive defining point of the lateral genu seen in oblique view.

The length of middle crura also determines the characteristic tip contours. "tip with inadequate projection" usually reflects short middle crura. To the extreme a "snub" nose is a result of very short middle crura (Sheen H., 2000).

### **Accessory cartilages of the nose :**

The term "sesamoid" may be applied to the minuscule cartilages between the lateral and alar cartilages and also the small cartilages in the superolateral portion of the ala (Fig. 6).

The term "accessory" cartilages is suggested to designate the larger cartilages that join the lateral crus to the edge of piriform aperture through the continuity of the perichondrium of these structures (Firmin and Le Pesteur, 1977).

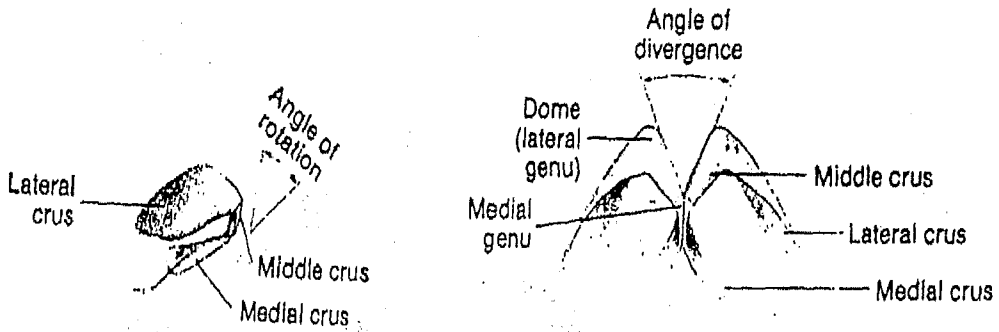


Fig. (5) : Three-segment anatomy of the alar cartilage. (Left) Angle of rotation at the medial genu defines the columellar-lobular junction; (right) angle of divergence determines the intercrural distance (Sheen J.H., 2000).

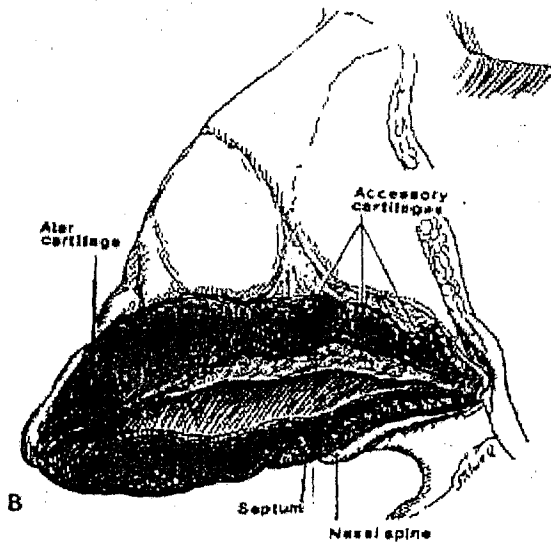


Fig. (6) : The alar cartilage and its accessory cartilages from a  $\frac{3}{4}$  circle narial ring (Courtesy of Firmin and Le Pesteur, 1977).

Although variable in size and shape, the accessory cartilages establish a bridge between the alar cartilage and the edge of the piriform aperture. Thus the alar cartilage and its accessory cartilages form a cartilaginous three - quarter ring at the base of the nasal pyramid.

### **Nasal septum and septal cartilage :**

The nasal septum is a midline structure that divides the nasal cavity into two lateral chambers.

The septal framework is composed of bony and cartilaginous constituents : the four bony components of the osseous septum (the perpendicular plate of ethmoid, the vomer, the nasal crest of the maxilla and the nasal crest of the palatine bone) and the septal cartilage.

The septal cartilage is a quadrangular lamina that forms the major portion of the framework of the caudal portion of the septum. It protrudes in front of the piriform aperture.

The septal angle is located immediately cephalad to the alar cartilage in the area referred to as supratip area.

The lower portion of the septal cartilage is firmly bound to vomer and premaxillary wings, the caudal part of the septal cartilage is more mobile and flexible. The caudal margin of the septal cartilage is separated from the columella (and medial crura) by the juxtaposition of two mucocutaneous flaps that form the membranous septum.

The cephalic portion of dorsal border of the septal cartilage, intimately connected with the cephalic portion of the lateral cartilages, extends under the nasal bones, where it is received in a shallow bony groove. The posterior border is connected to the perpendicular plate of the ethmoid, the

posterior extension of the septal cartilage separates a portion of the ethmoid plate from the vomer.

*Nostril border* : The border of the nostril is supported by dense cartilaginous tissue arranged in resilient longitudinal bundles. The lateral crus is closer to the caudal margin of the external naris border in its medial third but extends away from the margin in its lateral portion.

*Soft triangle* : the dome, point of union of the lateral and medial crura is separated from the margin of the nostril by a triangular - shaped area known as the soft triangle (Converse, 1955).

The soft triangle consists of two juxtaposed layers of skin, "the covering skin of the nose and vestibular skin" separated by loose areolar tissue (Fig. 7).

An incision through the soft triangle should be avoided as subsequent healing may result in a disfiguring notch.

The marginal incision for exposure of alar cartilage should follow the caudal margin of the cartilage and not the margin of nostril.

*Weak triangle* : The lateral crura of the alar cartilages diverge in the supra tip area, leaving a triangular - shaped area between them into which the septal angle is fitted (Fig. 8).

In many noses, the dorsum is supported only by the septal angle the alar cartilages which overlap the lateral cartilages are connected by aponeurotic-like tissue which also maintains the attachment of the alar cartilages to the septal angle and act as a suspensory ligament of the tip of the nose.

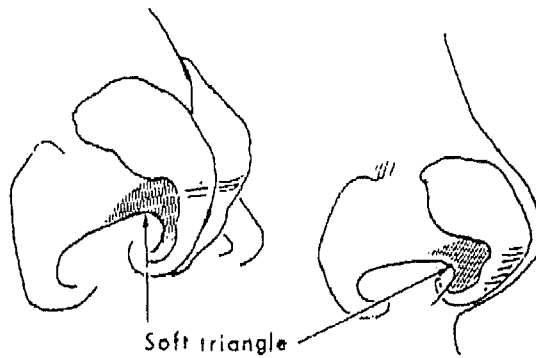


Fig. (7) : The soft triangle of the nose, consisting of two juxtaposed layers of skin separation the dome of the alar cartilage from the nostril border. The soft triangle is represented by the shaded area. Skin incisions should be avoided in this area (McCarthy and Wood Smith, 1990).

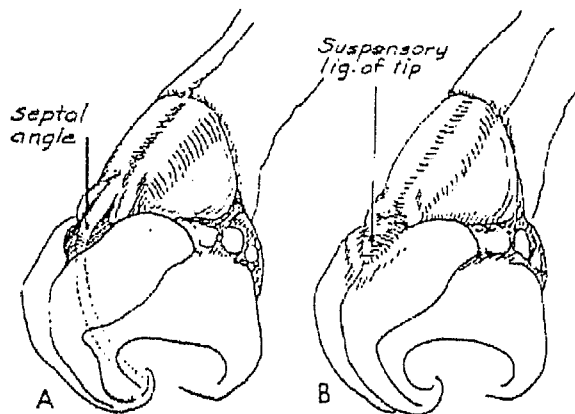


Fig. (8) : The weak triangle and the suspensory ligament of the nose. A) The soft tissues have been removed to show that the septal angle supports the area of the dorsum between and above the diverging lateral crura (the weak triangle). This area is subject to many anatomic variations. B) The aponeurosis joining the structures (the suspensory ligament of the nasal tip) (McCarthy and Wood Smith, 1990).

***Columella*** : The columella extends from the tip of the nose to the lip, joining the lip and the upper portion of the philtrum and separating the external nares.

The posterior portion of the columella is wider than the anterior portion owing to the divergence of the medial crura of the alar cartilages, the lower ends of which embrace the caudal margin of the septal cartilage. The lower portion of the columella is also wider because of the divergence of the medial crura of the alar cartilage.

The contour of the columella depends largely on the shape and divergence of these cartilaginous structures.

The medial crura curve down from the dome thus assuming a vertical position before the crura reach their vertical and sagittal position in the lower portion of the columella they form a facet at the turning point, "a fetal surface that breaks the continuity between the tip and columella". This area is the tip-columella angle, flanked on each side by the soft triangle. Below the angle, the remainder of the columella shows a gentle curve with a caudal convexity.

### **Nasal muscles :**

#### ***The procerus :***

It arises inferiorly from the aponeurosis of transverse nasalis muscle, periosteum of the nasal bones and the perichondrium of upper lateral cartilages. The fibers from these origins are frequently fused, as are the muscles from each side of the nose. They pass upwards to insert into the glabellar skin between eyebrows (Fig. 9c).

***Action :***

It pulls the skin above the glabella downward, causing characteristic transverse wrinkles at the root of nose.

The procerus has been described as being a continuation of the frontalis belly of the occipitofrontalis muscle (Krause C. et al., 1991).

As by virtue of its attachment at the aponeurosis of transverse nasalis muscle, the procerus has been described as raising the skin of the cartilaginous vault and the tip of nose (Griesman B., 1944).

***The nasalis muscle :***

It is composed of alar and transverse portions : (Fig. 9b)

A) *The alar portion* is often referred to as the pars alaris or dilator naris posterior muscle. Its origin is from maxilla above lateral incisor and canine teeth. Its fibers pass upward and anteriorly to insert into the skin of the posterior circumference of the alar, above the lateral crura of the lower lateral cartilage it also inserts into the posterior part of the mobile septum.

***Action :***

The muscle will draw the ala and the posterior part of the columella downward. This will assist in elongating the nose and also wider the nasal aperture.

The muscle helps with the fine control of respiratory resistance by its effect on the “nasal valve” or flow-limiting segment of the nose (Van Lunteren S.E. et al., 1985).

B) *Transverse portion* of this muscle originates from maxilla above and lateral to incisor fossa, lateral to the origin of pars nasalis.



It may receive fibers from the levator labii superioris alaeque nasi or it may interdigitate with procerus, it inserts into the aponeurosis that connects with that of the opposite side of the nose thus forming a sling.

***Action :***

Cause downward movement of the cephalic rim of the lateral crura.

It will elongate the nose by rolling these lower lateral cartilages downward and compress the vestibule.

***Levator labii superioris alaeque nasi :***

This muscle arise from the medial part of the orbicularis oculi and the frontal process of the maxilla (Fig. 9a).

The lateral fibers insert into the labial fold.

Central fibers pass around the ala nasi to the skin and muscle of upper lip.

The most medial fibers are attached into the ala nasi.

***Action :***

- Fibers passing to naso libial fold will raise and deepen it.
- Central fibers act on upper lip and help in narrowing the nostril.
- Fibers inserted into ala nasi will elevate it and help wider of nasal aperture.

***Depressor septi nasi :***

This muscle arise from maxillary periosteum above the central and lateral incisors as well as from anterior nasal spine. Some fibers come from upper fibers of orbicularis oris.

Insertion is into columella, the membranous septum and the base of medial crura of the nasal cartilage. Some fibers apparently pass between medial crura to the nasal tip (Vog T., 1983).

***Action :***

- Draws down of the columella, the tip of the nose and dorsal border of the nostril.
- Some of its fibers will lift the central lip while at the same time depress the nasal tip (Zide B., 1985).
- It may be involved in hypermobile tip, seen as the nasal tip bobbling up and down when the subject speaks or smiles.
- This muscle tenses the membranous septum at the initiation of nasal respiration.

***Anomalis nasi :***

This muscle is not always present.

It arises from the frontal process of the maxilla.

It inserts into the nasal bone, the upper lateral cartilage, the procerus and transverse part of the nasalis (Letourneau, A and Daniel R., 1988).

***Action :***

- It will compress and help to elongate the nose.

***Dilator naris anterior (apicis nasi) :***

It is a very small muscle that originates from the upper lateral cartilage and alar part of the nasalis (Fig. 9f).

It inserts in the caudal part of lateral crus and lateral alar skin.

***Action :***

- It will therefore dilate the nostril embracing the circumference of the nasal aperture.

***Compressor narium minor :***

It is a small muscle not always present (Fig. 9E).

It arises from the anterior part of lower lateral cartilage.

It inserts in the skin near the margin of the nostrils (**Lanza D. et al., 1991**).

***Action :***

From the position of its fibers, its action seems likely to slightly decrease the nasal aperture (**Clark M.P. et al., 1998**).

**Blood supply :** arteries of the external nose are the alar and septal branch of the facial artery which supply the ala and the lower part of the septum, the dorsal branch of the ophthalmic artery and the infraorbital branch of maxillary artery which supply the lateral aspect of the dorsum.

The veins end in the facial and ophthalmic veins.

**Nerve supply :** The skin of the nose receives branches from the ophthalmic nerve through its infratrochlear branch and external nasal nerve, and from the infraorbital branch of maxillary nerve.

**Vestibule :** The vestibule, the antechamber of the nasal fossa, forms the caudal portion of the floor of the nose and extends under the dome of the alar cartilages.

The vestibule is separated from nasal fossa proper by the caudal border of the lateral cartilage form a physiologic standpoint, this is the most important anatomic structure of the nose.

It is easily visible when one retract the ala, the lower border of the lateral cartilage protrudes. This area was termed the "limen nasi".

The vestibule is delimited cauded by medial extension of the alar border, the anterior narial fold. Thus along the floor of the nose, the vestibule is delimited by the anterior narial fold cauded and by the posterior vestibular fold cephalad.

The vestibule is lined by squamous epithelium contains numerous hairs and sebaceous glands.

The vestibule serves as air-conditioning apparatus, warming, filtering and moistening the inspired air (McCarthy and Wood Smith, 1990).

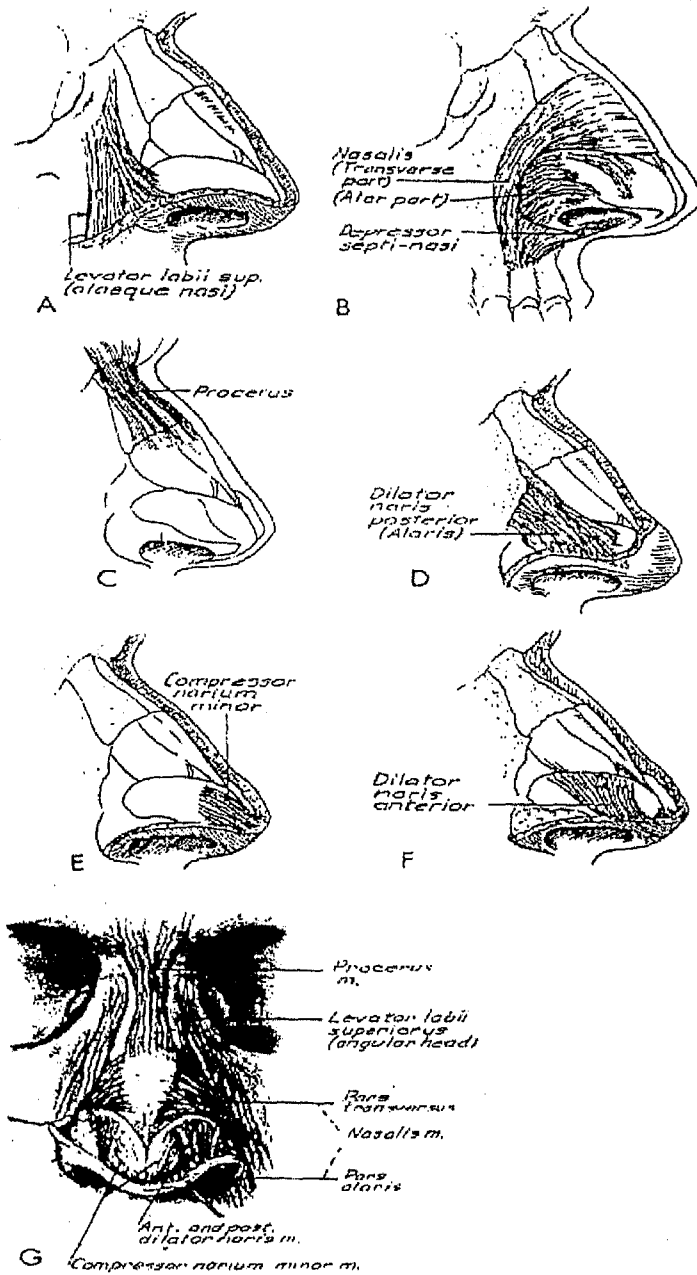


Fig. (9) : The muscles of the nose (McCarthy and Wood Smith, 1990).

## **PATHOLOGIC ANATOMY**

Cleft lip nasal deformity is very characteristic, its severity varies with each case and is directly related to the extent of lip deformity. Particularly the alveolar cleft.

### *Components of the nasal deformity include :*

Defects of lower lateral cartilages on the cleft side, the nasal septum, the columella, the nasal tip and entire nasal pyramid. The maxillary cleft and hypoplasia and malpositioning of the maxillary segments also contribute significantly to the asymmetry.

The anatomic and functional deformity of the orbicularis muscle also contributes to the nasal deformity. The etiology of unilateral cleft lip nasal deformity is still a subject of considerable debate.

Studies of the development of the facial area especially the medial and lateral nasal processes suggest an intrinsic defect or a deficiency of growth and development of the nasal structures.

Failure of neural crest cells to migrate result in absence of mesodermal penetration of soft tissues in the cleft region and is a possible cause (**Stark and Kaplan, 1973; Johnston et al., 1975**).

The growth disturbance can result from an inherited tendency (**Fogh-Andersen, 1942**) or from an environmental influence (**Fraser, 1971 Patton, 1971**). The degree of severity is related to the embryonic period in which the disturbance occurs, with misdirection during an earlier period causing even greater deformity.

Avery, (1961) studied the nasal capsule cartilage in the cleft deformity and compared with unaffected embryos and documented that the cartilage in the embryo with clefts was deficient and malformed and show delayed growth. In addition there were abnormalities of the vomer and contiguous maxillary bones.

The “isolated cleft lip-nose” concept seems to argue for an intrinsic tissue abnormality, a hypothesis supported only by (Brown, 1964).

Boo-chai and Tange, (1968) and Stenstrom and Thilander, (1965) reported abnormal canine and supernumerary teeth in these patients and, because of these finding, believe that the cleft lip nasal deformity is an expression of lip and palate diathesis. These researchers failed to examine the orbicularis muscle and underlying maxilla.

Most investigators believe that cleft lip nasal deformities result from tissue deficiency of the cleft lip, a deficiency of maxilla or abnormal muscular pull or nasal structures. They have emphasized the role of tissue deficiencies (extrinsic) to the nasal tissues (Jackson L.T. and Fasching M.C., 1990).

In general, the prevailing opinion is that two distinct factors are, in fact, responsible for the eventual development of the nasal deformity. First, there is a definite agenesis of tissue within the general vicinity of the cleft owing to a decrease in the quantity of both mesoderm and ectoderm. Second, there is an associated deformation owing to mechanical stresses located within the cleft margin itself (Rifley W. and Thaller R., 1996).

Huffman and Lierle, (1949) are credited with one of the earliest and most comprehensive descriptions of the pathologic anatomy, inherent in

the cleft nose. They classified these deformities in relationship to the more common or typical ones.

They noted that the septum was invariably crooked or maligned, with the most common deformity being a ventrocaudal deflection adjacent to the columella, whereas in other patients the septum was dislocated. They found that the most noticeable problem was related to the degree of asymmetry present in the lobule secondary to retrodisplacement of the lower lateral cartilage and hypoplastic maxilla. In addition they also found a shortened and ventrodorsally directed columella with a maldeveloped crura.

**Bardach and Salyer, (1987)** emphasized the individuality of the cleft lip nasal deformity; their description of the cleft lip nose included in addition to the above, nasolabial fistula, absence of the nasal floor, hypertrophy of the inferior turbinate on the cleft side, and displacement of the non-cleft maxillary segment.

**Berkeley, (1959) and Uchida, (1971)** described what was referred to as a vestibular web – a characteristic linear contracture of the interior nostril from its apex to the piriform aperture along the upper border of the alar cartilage.

This defect is due to anteroposterior shortness of maxilla (i.e. piriform aperture on the cleft side). There is general agreement on these observations, although **Broadbent and Woolf, (1984)** stated that the columella is not short and simply it extends laterally to a dipped area on the rim of the nostril.

It is true that the columella is not short, but it appears so owing to malpositioning because of the absence of the nasal spine on the cleft side.



A deficient piriform aperture and its adverse effect on the alar base have been emphasized by **Hogan and Converse, (1971)**.

**Ortiz-Monasterio and Olmedo, (1981), Jackson, (1984) and Anderl, (1985)**. Bone grafts, cartilage grafts and other materials placed on the piriform aperture have significantly improved the nasal contour by providing elevation of the alar base.

**Berkeley, (1969)** attributed the cleft lip nasal deformity to incomplete rotation of the alar cartilage. **Onizuka, (1972)** believed that nostril asymmetry was due to in part to absence of the alar base fullness on the affected side.

**Converse et al., (1977)** considered the pathologic anatomic features under three categories : The nasal tip (alar cartilage and columella), the lateral bony platform (piriform aperture) and the midline supporting structures (cartilaginous septum and anterior nasal spine) (Fig. 10).

**Hogan and Converse, (1971)** represented the unilateral cleft lip nasal deformity as a "tilted tripod" resting on a hypoplastic maxilla to explain the characteristic bending and deformity of nasal cartilages.

The tripod of the two ala and septum supports the nasal soft tissue. When one of the bony platforms (hypoplastic maxilla) is deficient, the tripod collapses on the ipsilateral alae and deflects the septum into the contralateral normal naris. When marked hypoplasia, the septum is lifted out of the vomerine groove and encroaches on the opposite nostril as occurs in 70 to 80 percent of unilateral cleft lip noses (Fig. 11).

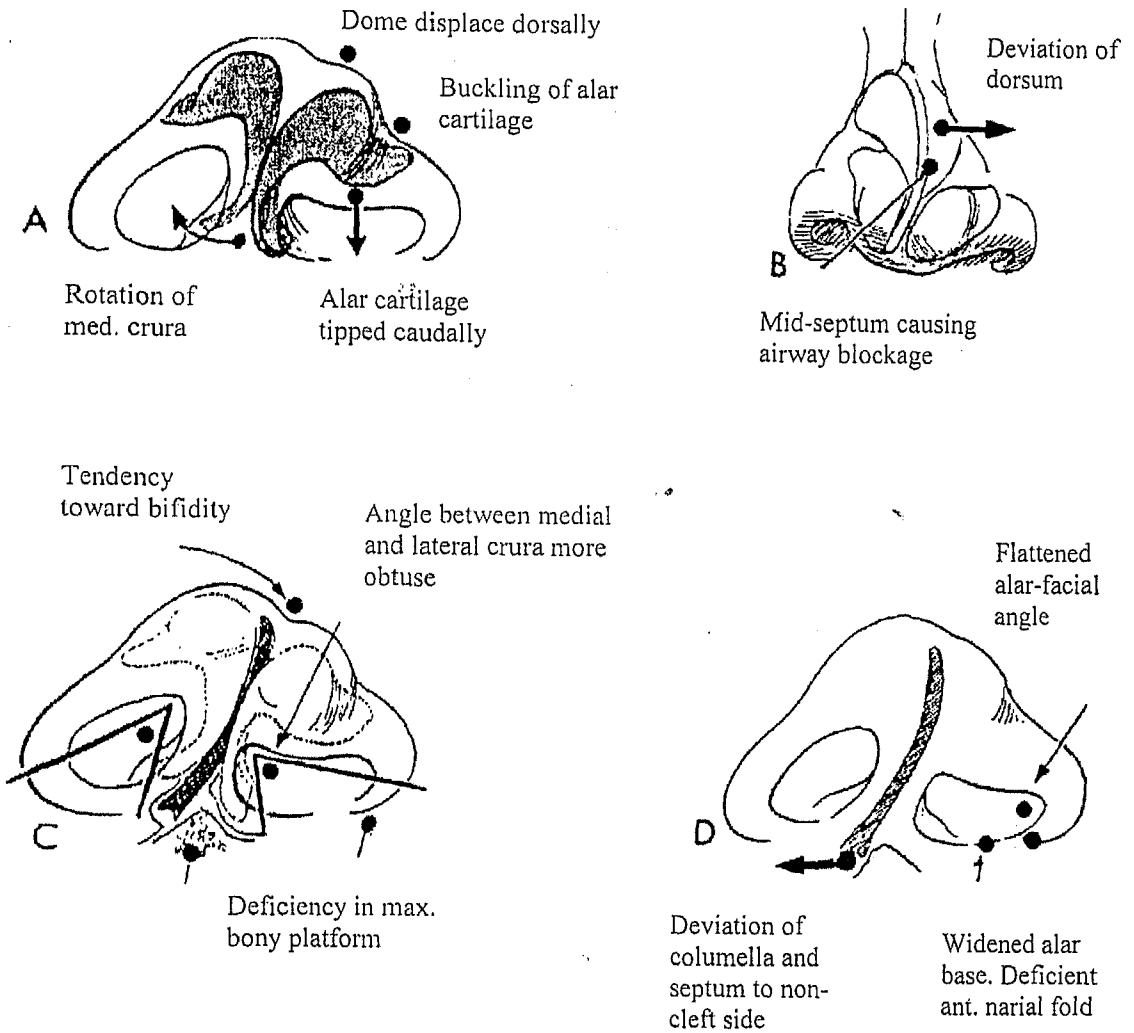


Fig. (10) : Deformities of the nasal tip in cleft lip nose. From (Converse J.M. et al., 1977).

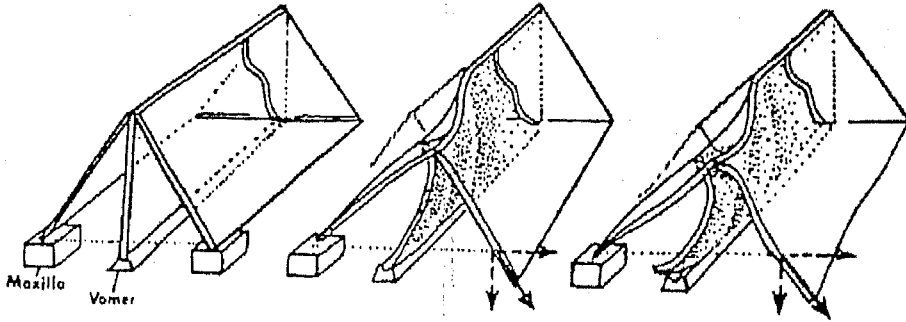


Fig. (11) : The tilted tripod. Left, schematic of the nose illustrates the basic tripod nature of the nasal structures. The tripod consists of the dorsal portion of the septum and nasal bones and the two alar arms. Middle, the tilting effect results from maxillary hypoplasia with secondary deformity of the septum and cleft ala. Right, a more dramatic illustration of the convex deformity of the septum and the vertical bending of the septum posterior to the junction of the membranous and cartilaginous portions of the septum is evident. Restriction of the caudal border of the septum in its anterior thrust causes it to bend toward the normal nostril. If there is a more severe deformity of the vomer, the septum is displaced into the normal nostril. (After Hogan V.M., Converse J.M., 1971).

**Hobar, (1994)** summarized the features of the cleft lip nasal deformity:

- The tip of the nose and caudal septum are deviated away from the cleft side.
- Convexity of the septum on the side of the cleft, impinging on the airway.
- The angle between the medial and lateral crura on the cleft side is excessively obtuse.
- The dome of the alar cartilage on the cleft side is depressed.
- The interior of the cleft side nostril, from its apex down the cephalic margin of the alar cartilage to the piriform aperture is bowed by a linear contracture, the vestibular web.
- The lateral crus is caudally displaced on the cleft side.
- The cleft side ala buckles inwardly.
- Absent alar – facial groove on the cleft side.
- Hypoplastic maxilla on the cleft side.
- Ill-proportioned nares, widened nostril floor on cleft side and retrodisplaced medial crus on the cleft side.

**McComb, (1986)** however, argue that the lower border of the lower lateral cartilage forms the vestibular web, he also noted that the nose is lengthened on the side of the cleft.

**Salyer, (1994)** observed that the lateral cruse of the lower lateral cartilage is longer on the cleft side.

The above-listed feature of the cleft lip nasal deformity are observations. The cause of the typical cleft deformity is less well understood, and numerous mechanisms have been proposed. Whether the nasal deformity is due to an intrinsic deficiency, or due to normal structures distorted by extrinsic forces, or due to a combination of the two, remains a matter of debate (Fisher M., 1998).

In general, the nasal septum exhibits considerable distortion and displacement, resulting in columellar base resting closer to the normal side of the nose than the tip. The columella slants obliquely and is shorter on one side of the cleft. Meanwhile, the inferior margin of the septum and vomer are connected to the greater maxillary segment, leading to the nasal spine lying within the noncleft nostril. The premaxilla located on the cleft side is deviated anteriorly and medially in a direction toward the cleft side. These problems are accentuated by associated malposition and hypoplasia of the maxillary segments.

The most obvious deformity centers around the malpositioned alar cartilage located on the cleft side. In general the alar cartilage is inferiorly and laterally subluxed. Often it will bend into the vestibule itself closer examination reveals that the medial crus may be located in a more dorsal position in relationship to the columella located on the cleft side. This further accentuates its shorter appearance, whereas the lateral crus is dislodged in a caudodorsal, direction, resulting in the jetting out of the caudal end. This relationship causes the characteristic vestibular fold. This distracted alar cartilage pulls both the overlying skin and nasal dome both downward and outward, thereby further flattening the nasal tip. In addition, this pulls apart the domes of both cleft and non cleft alar cartilages. This serves to obliterate the alar facial groove, because the cartilages meet the

face at an obtuse angle. In summary, the major nasal elements, including the septum, alar cartilage, columella, tip and maxilla are involved in varying degrees with the overall deformity (Rifley W. and Thaller R., 1996).

Whether cleft lip nasal deformity is caused by malpositioning of normal structures due to extrinsic mechanism or a secondary inherent deficiency of nasal development or both, a significant amount of secondary deformity can be prevented by a primary lip repair that also includes nasal correction. It is important to recognize that failure to reconstruct the nasal floor in the primary cleft lip repair leaves the nose attached directly to the lip through the intact orbicularis and to the palate through the lateral mucoperiosteum of the alveolar cleft. Thus, although the lip defect may improve with time, the primary nasal deformity will never improve. This is a basic tenet of cleft development. the small constricted nostril resulting from oversacrifice of the lip or nose element is difficult and should not be produced initially (Jackson L.T. and Fasching M.C., 1990).

The rotation - advancement repair of Millard preserves tissue, repositions the alar base, lengthens the columella, restores lip muscle continuity, reconstructs the nostril still and floor (if the primary palate is repaired), adds tissue for vestibular lining and generally offers the greatest opportunity for nasal corrections (Jackson L.T. and Fasching M.C., 1990).

## **TIMING OF CORRECTION OF UNILATERAL NASAL DEFORMITIES**

Repair of nasal deformities in the unilateral cleft lip patients may be done at the time of primary lip repair, in the preschool year (age 4 to 6 years), during puberty (age 10 to 12 years) or as an adult.

There is now less credence given to the concept of disturbance of nasal growth by surgery. The optimal time to attempt correction of a cleft lip nasal deformity remains contraversial (**Jackson L.T. and Fasching M.C., 1990**).

### **Primary unilateral cleft nose correction :**

The possibility of simultaneous primary lip and nose repair interfering with nasal and maxillary growth as a result of postoperative scarring was raised by **Marcks et al., (1964)** and **Mathews, (1968)**.

Direct surgical attack on the nasal tip or alar cartilages of the unilateral cleft lip nasal deformity in infancy presupposes the technical ability to work with small and fragile cartilages and the capacity to predict the outcome of developing structures, operating on the adult nose, in the opinion of these investigators offer the advantage of producing a definitive result. Correction at the primary lip repair was advised by **Berkeley, (1969)**.

Many authors argued that the future nasal configuration would be more satisfactory if the cartilages were in their correct position during the growth period. There is no evidence to support this hypothesis, over the last two decades, more radical correction of nasal deformity at the time of lip repair

has been described by **Pigott and Millard, (1971); Broadbent and Woolf, (1984); McComb, (1985); Salyer, (1986) and Bardach and Salyer, (1987).**

Early nasal correction in the unilateral cleft lip is now being accomplished at the time of definitive lip closure. This is possible because with presurgical orthodontics and gingivoperiosteoplasty the nasal platform is rendered symmetrical (**LaTham R.A., 1980**).

At the time of rotation advancement of the lip, the exposure enables columella lengthening, correction of the alar cartilages position and cinch of the flaring alar base (**Millard, D.R. and LaTham R.A., 1990**).

**Trott J.A. and Mohan N., (1993)** decided there were compelling reasons not only to perform correction of the nostril and nasal tip at the time of lip repair but also to capitalise on the benefits of the open rhinoplasty approach.

Their reasoning, while theoreticol, was based on both technical and socio-economic arguments :

1. Open rhinoplasty at the time of lip repair facilitates mobilisation and independent repositioning of unscarred key anatomy, including nasal mucosa, attached alar cartilages, orbicularis muscle, nostril skin and subcutaneous fat.
2. Restoring the anatomy of the alar cartilages from the earliest possible time in theory will allow growth to be vectored in an optimal way for as long as possible. This may have secondary benefits for the septal and upper lateral cartilages in terms of their future growth direction.
3. The above has the potential to minimize the number and extent of subsequent revisional procedures.



4. Correcting the nostrils at the earliest opportunity has the potential to minimize or eradicate the psychological trauma of a child growing up with the cleft lip nose stigma.

They believe that will enhance the child's self-esteem and social potential and is an argument to which they ascribe particular importance (Trott J.A. and Mohan N., 1993).

Early correction of unilateral cleft lip without associated nasal correction leaves the remaining problem of nasal asymmetry and deformity, which condemns the cleft patients to a childhood burdened by this nasal deformity. For many years, the nose was left untouched at the time of primary lip closure because of concern for the delicate infantile alar cartilages and their growth. Yet history has shown that early surgery on these cartilages does not affect growth (Millard D.R.Jr., 1996).

Primary nasal correction at the time of rotation advancement of the lip has been rendered practical by developing a symmetrical nasal platform by presurgical orthodontics and a gingivoperiosteoplasty. The nasal correction involves unilateral columella lengthening alar cartilages positioning and alar base cinching to present a nose within normal limits.

This is accomplished before the age of recall, and by avoiding retention of the nasal deformity through childhood. It bypasses the ridicule that invariably accompanies it (Millard D.R. and Morovic C.G., 1998).

Anastassov G.E. et al., (1998) established a correlation between aesthetic and functional nasal impairments in patients with cleft lip whose nasal reconstruction had been delayed. They found that, the degree of bnasal dimorphism correlated with the severity of the nasal functional impairments.

Delayed nasal repairs in patients with cleft lip did not produce satisfactory aesthetic or functional results, probably because growth was retarded and midfacial development was disturbed at the time of delayed rhinoplasty and resulted in asymmetry.

In cleft lip patients, the nose should be repaired during the early primary cheilorhinoplasty, as this is essential for the restoration of a normally functioning and aesthetically pleasing nose.

### **Preschool age :**

Many authorities agree that early correction of the nose in unilateral cleft lip patients during preschool years is indicated (Jackson, 1990).

Social pressures at age 4 to 6 years heighten the patient's awareness of residual cleft lip nasal deformity and consequently demands for correction intensity.

No body has the answer for the best time to perform revision surgery.

Surgeons develop during their careers a feeling for timing relative to each patient. Such feelings are based on a knowledge of the psychological and physical development of children. They usually perform nasal tip/columellar reconstruction at 4 to 6 years of age. When the children are entering kindergarten and first grade. The rest of secondary procedures, i.e., further nasal tip, and septorhinoplasty procedures are delayed until the mid teen years.

Since the parents are placing a great deal of trust and high expectations on each procedure, They did not perform nasal tip surgery unless there is a chance of significant improvement in appearance and function, for example, as one would expect in columellar lengthening. More definitive procedures requiring septoplasty, on lying grafting, osteotomies, etc are carried out at age 16 to 17 for girls and 17 to 18 for boys (Connelly M.V., 1993).

Millard, (1982) believed that alar cartilages are adequately developed and can be manipulated at this age.

Bardach and Salyer, (1987) delayed secondary correction until the patient was 8 to 12 years old for three reasons :

- 1) To allow completion of orthodontic correction of the skeletal base.
- 2) To allow as much growth and development of lower lateral cartilages as possible and thus to have stronger, more stable support for the reconstructed nasal tip.
- 3) To allow bone grafting of the hypoplastic maxillary segment on the cleft side, which when performed in patients aged 8 to 9 years results in a more symmetric alar base, improving conditions for successful nasal deformity correction at a later age.

Converse et al., (1977) recommended only closure of the anterior cleft nasal floor, repositioning of the flaring ala, and bone grafting of the hypoplastic piriform aperture. They preferred to delay secondary rhinoplasty until nasal growth had been completed. This occurs in females by age 16 and in males by the age of 18 years (Hajnisova, 1967).

Growth activity in the septal cartilage of the septoplasty patients from 6 to 35 years of age was studied by Vetter et al., (1983). Study after incorporation of a labeled sulfate in septal specimens indicated that the highest growth activity was in the suprapremaxillary and anterior border of the septal cartilage between the ages of 6 and 10 years. Thus, they recommended no septal resection or revision before age 20. Rhinoplasty performed before puberty has not been fraught with growth disturbances or poor long term results (Ortiz - Monasterio and Olmedo, 1981, Salyer, 1986).

**Ortiz-Monasterio** and **Olmedo**, (1981) "performed complete rhinoplasties" in 44 patients between the ages of 8 and 12 years. Three-fourths of the nasal deformities were associated with unilateral or bilateral cleft lip or cleft palate. Lateral and medial osteotomies, extensive alar dissection and septoplasty were performed in the majority of patients. There were no obvious growth problems during a five-year follow up.

Most authorities agree that early correction (during preschool years) of unilateral cleft lip nose is indicated.

Secondary correction of residual nasal deformity by limited septoplasty, reconstruction of the nasal tip and alar cartilages and cartilage grafts are also appropriate during preschool years (**Jackson L.T. and Fasching M.C.**, 1990).

It has been stated by various investigators that rhinoplasty can be performed at early ages without disturbing nasal and facial growth. Based on these considerations, we have advocated open rhinoplasty for severe cleft lip-associated nasal deformity during preschool age (**Nishimura Y. and Kumoi T.**, 1991).

The nasal development of these children has been observed closely, when reviewed several years after surgery, the results appeared to be reasonably satisfactory. However, as the patients approached their adolescent growth spurt at 15 years of age, undesirable features have become obvious. Each patient showed strikingly large nose, with large amount of subcutaneous fat, thick skin and a wide, round nasal tip.

These undesirable features seem to be peculiar to the patients who underwent early correction using the open method (**Takato T. et al.**, 1995).

### **Puberty/Adolescence :**

Delay of definitive rhinoplasty until the patient is 14 years of age is desirable.

According to **Bardach and Salyer, (1987)** by this age the canine teeth have erupted and bone grafting has been performed, thus, providing bony support for the nasal base with augmentation of the hypoplastic maxilla.

Osteotomies of the maxilla and correction of skeletal or occlusal abnormalities should precede definitive rhinoplasty as advancement of the maxilla may alter the nasal contour significantly.

Although, it has been advised to wait for one year after maxillary osteotomy before donning rhinoplasty (**Bardach and Salyer, 1987**). It is quite reasonable to correct nasal deformity after six months.

Definitive rhyinoplasty may include septal resection, osteotomies, cartilage or bone grafting and extensive dissection of the upper and lower lateral cartilages.

**Salyer, (1986)** summarized the principles of correction of the cleft lip nasal deformity as follows :

- 1) The more severe deformity, the earlier and more radical the secondary procedure should be.
- 2) Correction of nasal deformity is designed to improve form and function and alleviate psychologic stress.
- 3) Correction of nasal deformities includes the skeletal base, septum, tip and the alae.
- 4) Bone grafting and cartilage augmentation may be indicated.

**===== *Timing of correction of unilateral nasal deformities*=====**

5) Definitive rhinoplasty is performed when the patient is 14 years of age or older, and

6) Severe asymmetry of the skeletal base is a contraindication to definitive rhinoplasty.

The authors however would advocate much earlier correction for severe deformity.

## **SURGICAL CORRECTION OF UNILATERAL CLEFT LIP NASAL DEFORMITIES**

The management of the cleft lip nasal deformity remains the most difficult, involved and challenging aspect of cleft lip surgery (**LaRossa, D. and Donath, G., 1993**).

The cleft lip nasal deformity is a difficult problem confronting the plastic surgeon, various methods have been advised to repair a cleft lip and its accompanying nasal deformities. The goal of repair is to achieve the following :

1. Creating a symmetrical nose from the frontal and caudal views.
2. Making a nose with good facial balance.
3. Making a beautiful nose from the aesthetic point of view (**Onizuka et al., 1983**).

We can classify the repair of cleft lip nasal deformities into two categories : primary and secondary nasal repair.

1. Primary nasal repair: This means an attempt to correct the associated nasal deformities at the time of primary repair of the cleft lip.
2. Secondary nasal repair: This is performed on patients on whom no primary repair of the nasal deformity has been done or in whom nasal deformities remain even after the primary nasal repair was performed.

## **Primary unilateral cleft lip nasal repair**

Primary correction of the cleft lip nasal deformity at the time of lip repair attempts to restore the parity between the two alar cartilage. The multiplicity of methods described for alignment of the deformed cartilages testifies to the difficulty of first achieving and then sustaining correction of the deformity.

**Millard (1982)** presented a good description detailing of the history of cleft lip nasal repair and pointed out an obvious advantage to the use of the advancement – rotation flap in correction of unilateral cleft lips because this leads to improvement in the so-called alar flare. In addition, he also simultaneously lengthened the columella, advanced the alar base by cutting it free, and secured it to the septum with sutures. This will also lift the alar cartilage. Millard points out that in his vast experience he has not associated growth abnormalities with early cartilaginous manipulations.

**Broadbent's (1984)** was another proponent of primary intervention. His Technique included. Extending the incision from the nose to the superior bucco-labial sulcus and undermining the lower lateral cartilage to release it from the tip, followed by suture fixation of the upper and lower cartilages within the tip region. The alar base is then carefully advanced toward the columella to avoid the untoward sequela of stenosis. Unfortunately, he concludes that the end results were far from satisfying. This general dissatisfaction with primary repair led to some rather extensive secondary procedures to correct the residual deformity.

**McComb, (1985)** provided one of the earliest long-term retrospective reviews detailing primary cleft lip rhinoplasties.



His article provides photographic documentation of his postoperative results in 10 patients with a minimum of 10-years follow-up. He focuses primarily on achieving an alar lift by passing a mattress suture through the intercrural angle and the lateral crus of the alar cartilage and then exiting at the level of the nasion. These are then held in place by suture bolsters. This give further credence that primary rhinoplasty does not interfere with ultimate facial growth and development.

Salyer, (1986) presented his 15-year follow-up on patients who underwent primary correction of the cleft lip nasal deformity. He reported on an impressive 400 unilateral cleft lip-nasal repairs. He goes on to list the four important steps that he feel's are necessary to attain the desired goal :

- (1) dissection of the lower lateral cartilage from the skin and lining.
- (2) shifting and repositioning of the lower lateral cartilage and redraping the skin and lining.
- (3) creation of a symmetrical ala and nasal tip.
- (4) creation of a symmetrical alar base.

Salyer demonstrated consistent results and firmly believed that early correction contributed to both normal nasal growth and psychosocial development.

Spira et al., (1970) reviewed and categorized treatments and proposed their own technique for correcting the nasal deformity accompanying the unilateral cleft lip.

They classified corrections using external incisions with and without rotational advancements, incision approaches to the tip, repositioning of the lower lateral cartilage, grafting procedures to the tip, columella, and/or underlying maxillary base and external and internal Z-plasties to secure

additional vestibular skin. Their technique basically used a "Flying bird" type incision followed by repositioning of the lower lateral cartilage and correcting the maxillary hypoplasia combined with standard septorhinoplasty.

**Skoog, (1969)** underscored the importance of muscle reconstruction during primary lip repair. He believed the muscles provided the foundation and stimulation for nasolabial development and morphology.

**Delaire, (1978)** have also stressed the importance of the muscles in the nasolabial region when performing primary or secondary cleft deformity.

Delaire theorized that the muscles of the anterior face are arranged in three circles, the superior ring consisting of the transversalis, levators, and piriformis musculature around the nasal region; a middle ring around the mouth formed by external and internal bands of orbicularis; and a lower ring around the chin made up of the mentalis and depressor labii musculature. When muscular ring is disrupted by a cleft, the positive musculo-periosteal influences that determine normal facial growth and development are likewise disturbed (Fig. 12). The maleffects of the misplaced musculature are evident at birth and will continue after cleft lip repair if attention is not given to careful restitution of the orofacial rings (**Markus A.F. And Delaire, 1993**).

**Schendel, (1991)** stated that the goal of surgery in primary cleft lip repair should be restitution of the periosteal musculo-aponeurotic system through careful dissection, identification and reconstruction of the oronasal musculature. Many surgical procedures do not specifically address this goal of surgery, rather, a limited orbicularis repair is done through standard lip incision. Some surgeons perform nasal procedures concurrent with lip repair to achieve a more desirable result (**Huriwitz D.J., 1990**).

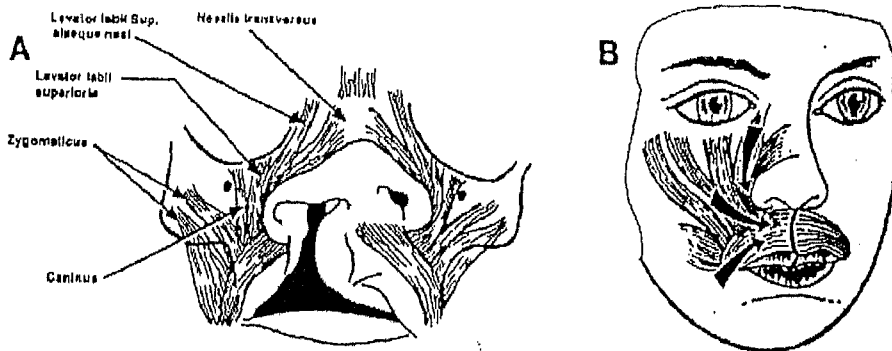


Fig. (12) : Schematic demonstrating muscular repair with mobilization and suturing to the midline of nasalis, levators and orbicularis musculature (Horswell B.B. and Pospisil O.A., 1995).

**La Rossa and Donath, (1993)** have utilized a five-step technique for primary correction of the unilateral cleft-lip nasal deformity.

**1. *Wide undermining of the nasal tip cartilages :***

The medial and lateral crura of both alar cartilages are widely undermined between cartilage and overlying skin laterally and between medial crura medially through the medial lip incision at the base of columella, the incision is used to release the attachment of the lateral lip element to the maxilla and to free their skin attachments. An intercartilaginous incision should be avoided because of the risk of nostril stenosis in the growing child (Fig.13a).

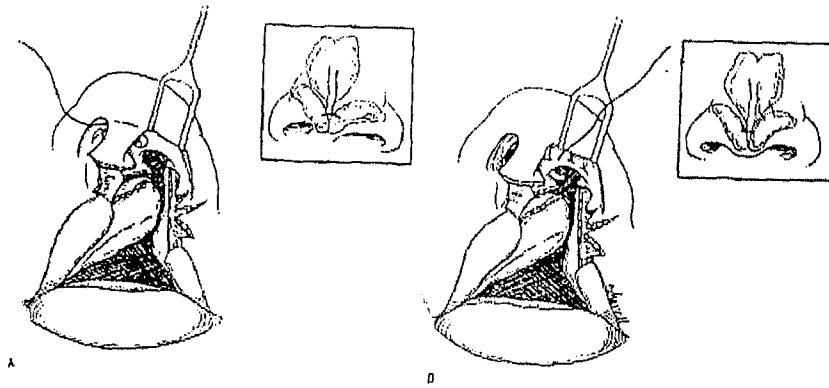
**2. *Repositioning of the cleft lower lateral cartilage :***

The lateral crus, dome and medial crus are pulled superiorly over the upper lateral cartilage to restore the normal overlap. The surgeon uses internal through and through absorbable mattress sutures along the ridge of overlap of the upper and lower alar cartilage (internal valve) and across the dome as a transfixion suture; alternatively, external suture on bolsters may be used to maintain the new anatomy during healing as described by **McComb, (1985)** (Fig. 13b).

**3. *Alar base flap :*** A v-shaped flap incorporating the alar base helps to rotate it medially.

**4. *V-Y advancement flap :*** Closure of the nostril floor. This can help to create a curved rather than a grooved floor and a narrow constricted nostril can theoretically be widened by moving the flaps apart in a secondary correction.

**5. *Muscle reconstruction :*** Muscle repair with a attachment of the upper slips of the medial muscle near the alar base help to move it medially. The uppermost slips of the lateral muscle can be attached near the base a columella, helping to move it medially.



**Fig. (13) : Primary nasal reconstruction with transfixion sutures through-and-through internal nasal valve sutures to adjust the position of alar cartilage on the cleft side relative to the noncleft side (La Rossa D., 1999).**

Trott A. and Mohan N., (1993) presented a preliminary report on open tip rhinoplasty at the time of lip repair in unilateral cleft lip and palate.

***Method :***

Their procedure was a modification of Millard's, (1964) rotation advancement lip operation combined with modification of Harashina's, (1990) Technique for secondary correction of the unilateral cleft lip nose.

***Planning :***

The Cupid's bow highlights was marked on the vermilion cutaneous junction of the medial segment.

Points were also marked at the junction of the columella and philtrum on both the cleft and non-cleft sides. A third point was marked at the mid-point of the junction of columellar base and philtrum. The Millard "C" flap was drawn to have its base between the two points on the cleft half of the columellar base (Fig. 14). A line was extended up the cleft side of the columella onto the skin of the nose tip to define a columella and nostril rim that was approximately symmetrical with the non-cleft side. The rim of the columella and the nostril on the non-cleft side was also marked. The lateral element (Millard's "B" flap) was drawn to include a modified triangular "white roll" flap with a base of approximately 2 mm.

***Dissection :***

This begins on the lateral side. All orbicularis muscle was preserved but freed from nasal mucosa down to the piriform margin. The muscle was also freed from the skin laterally to a line equivalent to the naso-labial groove. Subperiosteal dissection of nasal mucosa was carried out down the medial wall of the maxilla (Fig. 15). The nasal mucosa was incised along

the margin of the hard palate cleft and through the alveolar cleft, providing abundant lining for use in reconstruction of the floor of the nose and allowing anterior movement of the nostril base.

Subperiosteal dissection was carried across the anterior maxilla to the zygoma, permitting tension free advancement of cheek soft tissue across the bony cleft (Fig. 16).

The C-flap was dissected from below up and then continued into the columella, separating the skin from the medial crura of the alar cartilages. The fibro-fatty tissue between the domes of the alar cartilage was carefully freed and left attached to the overlying skin. The dissection continues over the remainder of the nasal skeleton, thereby freeing the skin widely over the entire nose.

Next the orbicularis muscle was freed from its attachment to the nasal spine and septum, which will allow the downward rotation of the medial element muscle.

Finally a vomerine flap was raised with extension through the alveolar cleft.

Suturing begins with the vomerine flap and lateral element nasal mucosa being approximated to reconstruct a nostril tube from posterior hard palate through to the nostril sill anteriorly.

The lateral element labial mucosa was then brought across the cleft and sutured to the medial element labial mucosa from the sulcus superiorly to the level of the vermilion inferiorly. No attempt was made to place a second flap through the alveolar cleft where the repair remains a single layer.

Next the orbicularis muscle from both sides was brought together for suture. Following the rotation advancement principle, the upper corner of the lateral element muscle was advanced across the base of the columella into the space created by the downward rotation of the medial element muscle. In addition a 2-3 mm cut was made in the muscle on each side at the level of the vermilion cutaneous junction. Placing a suture across and into the base of each cut will effectively "lock" the deep sphincteric component of the muscle within the vermilion (Fig. 17). Like Dado, (1990) they believe that the method of muscle repair was a more important determinant of resultant lip morphology than the skin method. The vermilion cutaneous junction triangular flap was sutured, as was the vermilion mucosa, and the "B" flap was also advanced and sutured using 6/0 nylon.

Next the columella was elevated with a skin hook. This manoeuvre tends to align the alar cartilages. Two to three 4/0 vicryl sutures are used to suture the medial crura and alar domes. The cranial edges of the lateral crura were sutured, securing the upward rotation of the lateral crura on the affected side (Fig. 18).

One or two sutures was placed transversely across the subcutaneous tissue deep to the nasal tip skin to create a soft tissue pad in this area. A further suture was placed through the deep dermis above the nasal tip soft tissue and tied down to the alar domes. This suture has the purpose of advancing the dorsal nasal skin downward and locking the nasal tip soft tissue pad over the alar cartilage dome (Fig. 19). Finally the nostril and columella rims were sutured and the nostril base adjusted for symmetry with the opposite side before it was sutured. The "C" flap was tailored into the space above the "B" flap in the manner of a Z-plasty (Fig. 20).



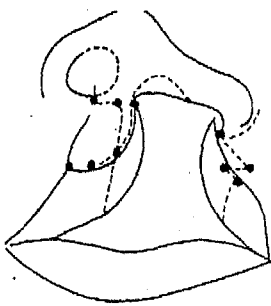


Fig. (14) : Diagram of planning lines showing modification of millard's rotation advancement method and Harashina's open rhinoplasty technique (Trott A. and Mohan N., 1993).

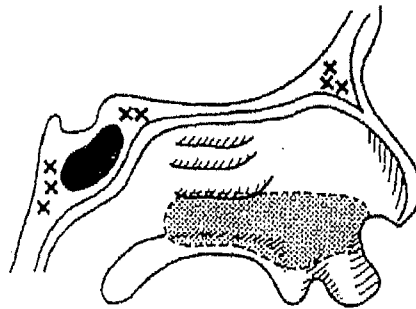


Fig. (15) : The shaded area depicts the extent of mucoperiosteal undermining on the medial wall of the maxilla (Trott A. and Mohan N., 1993).

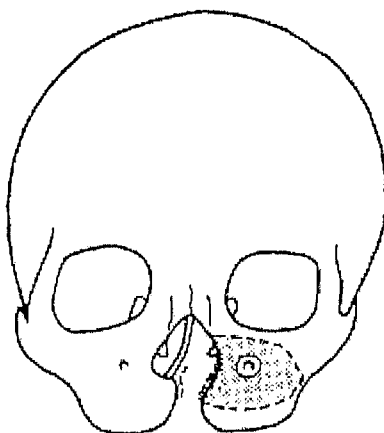


Fig. (16) : Diagram of planning lines showing modification of millard's rotation advancement method and Harashina's open rhinoplasty technique (Trott A. and Mohan N., 1993).

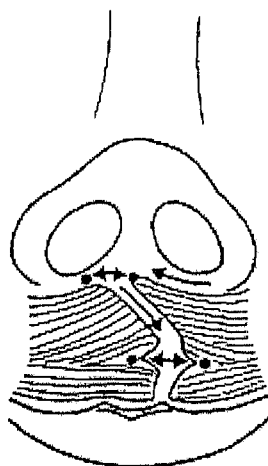


Fig. (17) : Methodology of orbicularis muscle repair. The medial element muscle has been separated from nasal spine and septum and rotated inferiorly. The superior edge of the lateral element muscle has been advanced into the defect created. Small back-cuts in the muscle at the level of the white-roll are sutured together to displace inferiorly and "lock". The deep sphincteric component of the muscle within the vermilion (Trott A. and Mohan N., 1993).



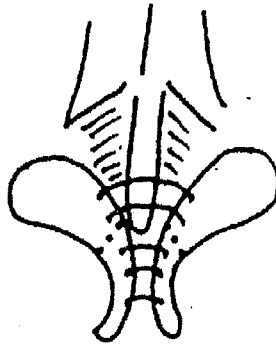


Fig. (18) : The medial crura, domes and cranial edge of the lateral crura are sutured using 4/0 vicryl (Trott A. and Mohan N., 1993).

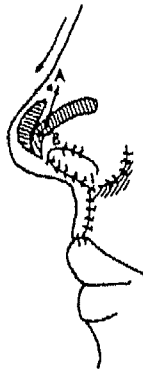

Fig. (19) : A suture is passed from the deep dermis just above the nasal tip soft tissue pad (point A) down to the alar domes (point B). This advances the dorsal nasal skin to augment the tip and columella as well as locking the nasal tip fat pad over the alar cartilage domes (Trott A. and Mohan N., 1993).

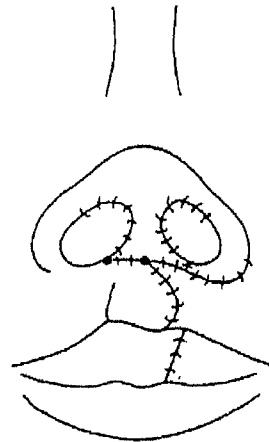


Fig. (20) : Suturing of the nostril rims is completed followed by tailoring of the nostril sill and nostril base. In this technique the C-flap is used to augment nostril sill and upper lip skin. The B-flap is advanced only as far as the midpoint of the columellar base (Trott A. and Mohan N., 1993).

Millard D.R. and Morovic C.G., (1998) presented primary unilateral cleft lip nasal correction with 10-year follow up:

*Maxillary Alignment :*

As soon as the patient weight 10 pounds, presurgical orthodontics using the Latham appliance was begun (Latham, 1980).

Alignment of the maxillary segments was achieved in a few weeks.

A gingivoperiosteoplasty locks the alveolar segments into a more normal position, closing the anterior cleft and presenting a sound, symmetrical platform for the lip and nose. (Fig. 21). At the time of gingivoperiosteoplasty, lip closure by adhesion was performed, reducing tension of the primary lip closure and rendering a complete cleft into an incomplete one. Waiting 6 months before the next surgical step was strongly advised.

*Septal Correction :*

In a unilateral complete cleft. the septum unattached on the cleft side was displaced toward the non-cleft side of the nose from above downward with its base dislocated out of the vomerian groove.

There was a considerable widening of the distance between the anterior nasal spine and the piriform margin in both coronal and sagittal planes (Fig. 22a).

With the alignment of the two maxillary segments, the septum was corrected as it pivots in the vomerian groove, and it gradually assume a more vertical position in most of cases (Millard, 1994) (Fig. 22 b, c).

With this remarkable improvement of the maxillary alignment and septal position, by the age of 6 to 7 months, the lip can be rotated and advanced and primary nasal correction can be achieved at the same time.

The alar cartilage on the cleft side was dislocated from its mate on the normal side, was displaced down in the shortened columella, and was stretched laterally along with the flaring of the ala. At the age of 6 months, the alar cartilage had grown enough to allow careful dissection and manipulation. At the time of rotation and advancement of the lip, a C-flap was designed to lengthen the short side of the columella. Its tip was transposed into the upper portion of the lip cutback. Then through one-sided membranous septal incision, the columella can be advanced toward the nasal tip to increase symmetry. The unilateral membranous septal incision had been extended directly up to the alar margin and access to the medial two-thirds of the displaced alar cartilage was obtained (Millard, 1982).

The medial two-thirds of the displaced alar cartilage was freed from the overlying skin and from the thin adherent mucosa of the vestibule with careful sharp dissection. The freed medial two-thirds of alar cartilage was shaped if necessary and advanced to the opposite normal alar cartilage with a mattress suture of 4-0 prolene to reconstruct the medial crus.

A second, similar suture ensures the alar cartilage arch position with a stitch in the septum.

The lengthened columella was advanced on the cleft side, and the lining incision was closed carefully.

The alar cinch with its denuded tether sutured to the anterior septum, reconstructs the nostril still and reduces the alar flare to symmetry with the opposite side (Millard, 1994).

The lateral lip flap was advanced into the rotation gap to complete lip construction. This general technique has been used since 1980, and early results were shown in 1992 (Millard, 1992).

Over the past 10 years, the approach has been perfected. The results show symmetry of alar cartilages in the tip, unilateral columella lengthening, and the base balance with acceptable nostril symmetry.

This was all completed by the age 6 to 8 months. If normal growth of the nose produces an unaesthetic result (a hump, hook, bulbous tip, etc) a corrective rhinoplasty at the age of 16 year was then available (Millard D.R. & Morovic C.G., 1998).

Armstrong G.T. et al., (1997) presented a method of primary nasal correction utilizing presurgical orthopedics with Latham dentomaxillary advancement appliance, concomitant rotation – advancement cleft lip repair, gingivoperiosteoplasty and immediate correction of the nasal cartilage distortion with an “open technique” utilizing the rotation – advancement incisions.

Direct elevation and suture fixation of the cleft side alar cartilage was performed as well as recreation of the normal upper lateral / lower cartilage relationship, repair of nasal web, and release the vestibular lining utilizing an L. flap pedicled to the alar base.

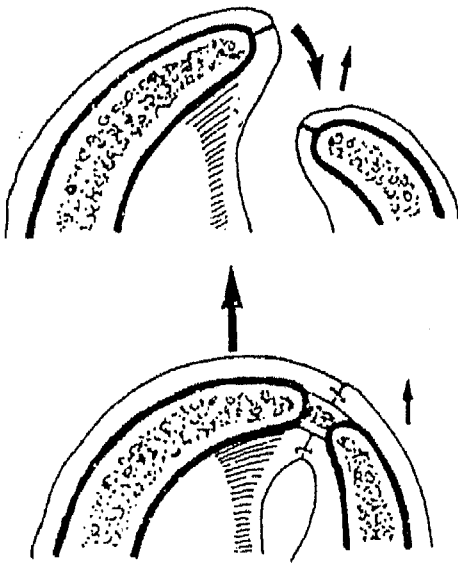


Fig. (21) : Presurgical orthodontics align the alveolar segments. A gingivoperiosteoplasty stabilizes the alignment, presenting a reasonably symmetrical platform for lip and nose (Millard D.R. and Morovic C.G., 1998).

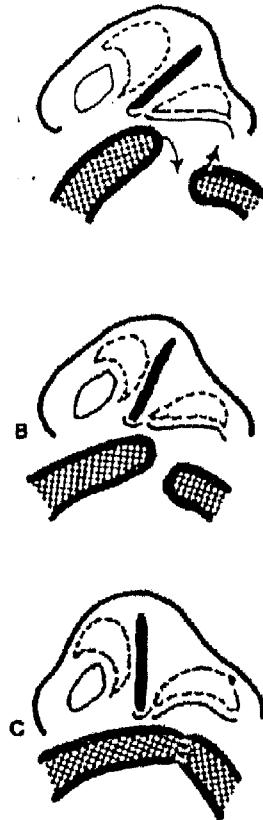


Fig. (22) : Presurgical orthodontics, gingivoperiosteoplasty and lip adhesion by aligning the alveolar segments, position the septum in a more upright position (Millard D.R. and Morovic C.G., 1998).



## **Secondary Correction of Unilateral Cleft Lip Nasal Deformities**

Secondary cleft lip nose deformities offer a continuing challenge to the rhinoplastic surgeon. The goal of a symmetrical nose that is harmonious with the rest of the face and functions well not attain easily (**Connely M.W., 1993**).

No single procedure developed to date has given sufficiently satisfactory results to provide a surgical standard for cleft lip nasal deformity correction.

Familiarity with the wide range of repairs is necessary to choose the appropriate technique for each patient.

The various techniques for correction of unilateral cleft lip nasal deformity has been listed by **Rohich and Tebbetts, (1987)** :

- 1) External approach.
- 2) Alar cartilage mobilization and suspension.
- 3) Alar cartilage incision and repositioning and
- 4) Graft augmentation.

Additional techniques include orthognathic procedures, bone grafting, vestibular web revisions and nostril hood modifications.

### **Rotation of cleft lip lobule and external incisions :**

**Blair, (1925)** noted that the width of the nostril on the cleft side was almost always increased. In addition, the alar base remained in association with the hypoplastic maxilla.

He initially carried out superior and medial rotation of the alar base to correct the abnormal orientation of the nares, and he advanced the downwardly displaced medial crura by a midcolumellar incision that extended under the alar base.

This procedure elevated the dome and narrowed the alar base but left the caudal of dislocation of the alar margin to be corrected by a wedge excision.

Modifications of Blair technique of excision and rotation advancement were described by (Morel-Fatio and Lalardrie, 1966).

This operation resulted in external scarring and fortunately has been abandoned in most centers.

**Berkeley, (1959)** described a more extensive rotation upward and medially of the entire half of the nose on the cleft side. The same technique advocated by **Velazquez and Ortiz-Monasterio, (1974)**.

Correction of flaring alar base, downward displacement of alar dome and inferior medial displacement of the medial crus results from the extensive mobilization of the lobule complex.

Instead of rotating the nostril floor into the columella. **Hugo and Tumbusch, (1971)** incorporated lip skin and scar to lengthen the columella on the cleft side.

Routine intranasal incisions provide adequate exposure of the lateral and medial crura although this approach is not satisfactory as that afforded by the external incision. Through a combination of rim and upper labial sulcus incisions, **Black, (1982)** was able to deglove the lower nasal skeleton and enhance exposure. "C-flap" extensions as described by **Tajima, (1983)** are an additional means of simultaneous exposure and skin

tailoring. Often secondary revisions of the lip and nose defects are combined.

*Proponents of external incision site the following advantages :*

- 1) Wide exposure.
- 2) Increase alar mobilization.
- 3) Possibly enhanced long-term stability and
- 4) Superior correction of severe deformities.

The major disadvantage of some external incisions is the presence of a scar on the nasal tip.

External incision were advocated by (**Crikelair Ju and Symonds, 1959**) in the following situations :

- 1) Severe deformities.
- 2) Thick alar skin and,
- 3) Previous unsuccessful procedures.

**Salyer, (1986)** used an incision described by **Berkely, (1969)** without extension into the nostril or over the nasal tip (Fig. 23).

Intranasal rim incisions connected across the columella at different level have been advocated by several investigators **Spira, et al, (1970)** were not advised.

Since placement of the incision at the columellar base and development of a columellar flap produces a less noticeable scar and allows excellent access to alar cartilage (**Uchida, 1971; Schwenger, 1973; Bardach and Salyer, 1987b**). This is the only acceptable external approach. Since, it is also used when indicated in esthetic rhinoplasty.

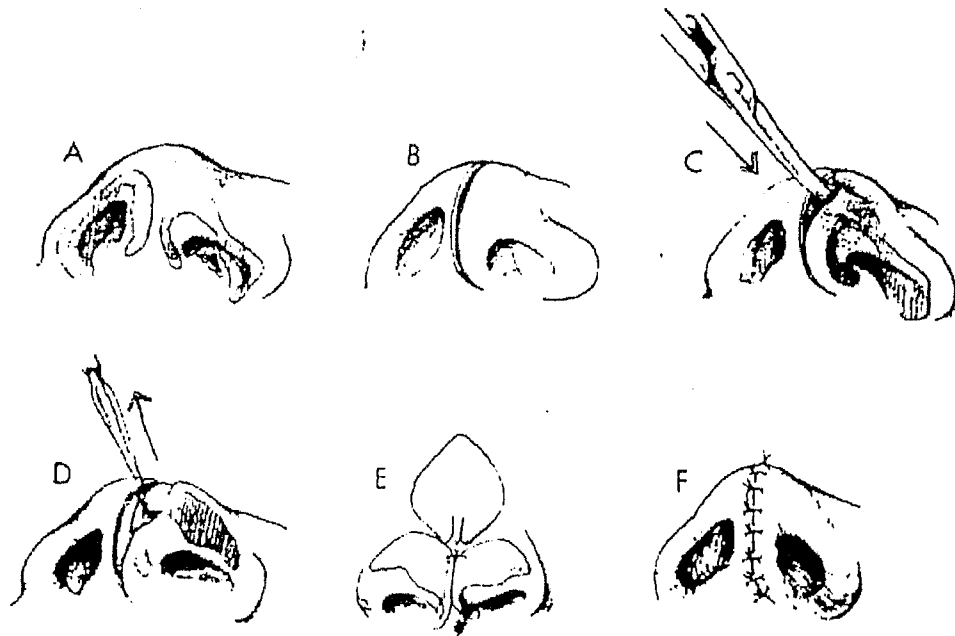


Fig. (23) : Method of exposing and correcting lower lateral cartilage deformity :

- a) The deformed and displaced lower lateral cartilage on the cleft side.
- b) The incision starts along the nasal sill and extends up to the midline of the columella and over the nasal dome to create access to the domes and lower lateral cartilage.
- c) Dissection of the skin from the lateral crus of the lower lateral cartilage.
- d) Elevation of the medial crura, exposing the septum.
- e) The lower lateral cartilage on the cleft side has been elevated and matched to the cartilage on the non cleft side by advancing it superiorly and cephalad, correcting the slumped tip.
- f) Closure of the external incision using interrupted 6-0 nylon suture preferably, pull-out prolene of 4-0 or 5-0.

After Berkerley from Bardach J. and Salyer K.E., (1987).

### **Alar cartilage mobilization and suspension :**

Long-term maintenance of cleft lip nasal deformity correction requires accurate placement of the nasal supporting structures (i.e. alar cartilages). Sufficient surgical exposure for dissection of the alar cartilage from the vestibular and external skin is essential for correction of the alar deformity and this can be achieved through intranasal incision. Various types of intranasal incision have been described by **Broadbend and Woolf, (1984)**.

Adequate exposure of the dome area and the medial and lateral crura can be obtained although not as completely as through an external incision. Nevertheless, in severe nasal deformity especially after multiple previous procedures and in bilateral cases. The external approach is recommended (**Jackson L.T. and Fasching M.C., 1990**).

Regardless whether intranasal incisions or external incisions are used, maintenance of the cleft alar components in their proper anatomic position after dissection and mobilization is crucial. The likelihood of success is limited in the presence of marked deformity or attenuation of the cleft alar cartilages, disruption of delicate structures during dissection or significant preexisting scarring (**Rohrich and Tebbetts, 1987**).

Complete exposure of the deformed alar cartilage, delivery of lateral crus and suturing of the domes are important components in the nasal correction of **Potter, (1954)**. The columellar flap was raised, exposing both lateral crura, in his technique (Fig. 24a).

**McIndoe and Rees, (1959)** described a procedure that involved exposing both alar cartilages and securing the alar domes to each other and to the septal angle. The lateral cartilages and crura were secured by sutures to the septum and by mattress suture through the skin, respectively (Fig. 24b).

A raw defect in the lateral vestibule either was closed with a composite graft of cartilage and skin or was left to epithelize.

**Rees, et al , (1966)** dissected the entire lateral crus on the cleft side from the nasal skin and mucosa and weakened the cartilage by scoring to establish a contour similar to that of the noncleft dome. Sutures to the contralateral upper lateral cartilage and medial crura maintained the corrected height of the dome, the lateral vestibular defect was closed with a skin graft or composite chondrocutaneous graft (Fig. 24e).

Suspension of the cleft lateral alar crus to both ipsilateral and contralateral upper lateral cartilages was described by **Reynolds and Horton, (1965)**. Elevation and suspending of the cleft alar cartilage are facilitated by excision of a portion of alar cartilage (cephalic edge) (Fig. 24d).

**Tajima and Maruyama's, (1977)** described a reverse U-incision with suture suspension of the repositioned alar cartilages (Fig. 24i).

On the nostril on the cleft side a reverse u-incision begins in the membranous septum, curving forward slightly over the nostril rim parallel to the dome of the cartilage and reentering the nose to end lateral to the fold in the nasal vestibule, a chondromucocutaneous flap of the alar cartilage is raised and widely undermined.

Additional undermining over the contralateral alar cartilage and upper lateral cartilage frees the entire nasal skin for redraping the deformed alar cartilage flap is properly positioned and sutured to the contralateral alar cartilage of noncleft side and the lateral cartilages of both sides by rotating the reverse u-flap medially and superiorly.

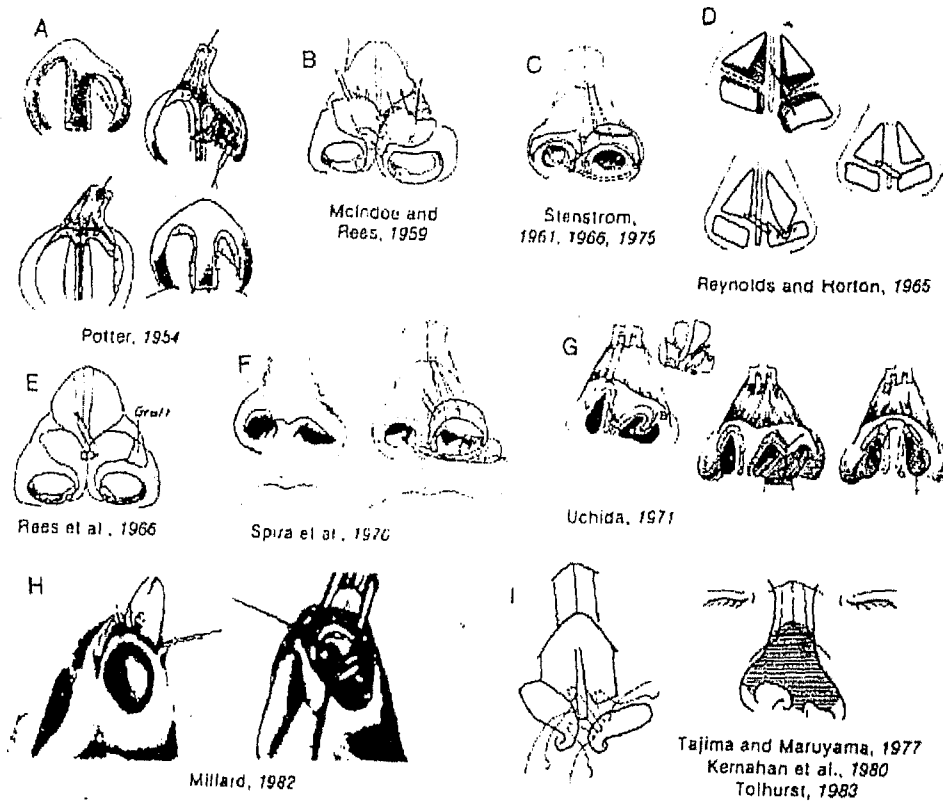


Fig. (24) : Selection of methods for suspension of the deformed lower lateral cartilage (Jackson L.T. and Fascing M.C., 1990).

Since **Tajima et al., (1977)** describe their technique many surgeons have applied it with some modifications.

**Kernahan et al., (1980)** introduced the use of cleft lip nasal retractor to make suturing of the nasal cartilage more easy.

He stated that, although the cartilaginous skeleton can be visualized through the incision, the difficulty in passing the needle through the upper lateral cartilage and dome on the normal side led to modify and simplify the early technique of suture placement.

A Senn retractor was specially modified by one of the authors to leave a metal rim and open centre (Fig. 25) the retractor is placed through the incision and into the widely undermined space between the cartilaginous skeleton and overlying skin and can be directed freely over either upper lateral cartilage or the dome on the normal side.

The 4 – 0 nylon sutures are double armed with straight Keith needles, which are placed from within the nose through the mucosa and cartilage and out the dorsal skin. The needle passes through the opening in the retractor blade. As the retractor is withdrawn, the suture is pulled backward through the skin and out the incision, leaving it firmly attached to the mucosa and cartilage in the desired position. A gentle sawing action on the suture cuts the loop through nasal mucosa, leaving it attached to the cartilage only (Fig. 26).

After these deep suture have been secured, the suture placement to the alar cartilage on the cleft side become a simple matter under direct vision, using a free lane's cleft palate needle (**Kernahan et al., 1980**).






Fig. (25) : The cleft lip nasal retractor (Kernanan et al., 1980)

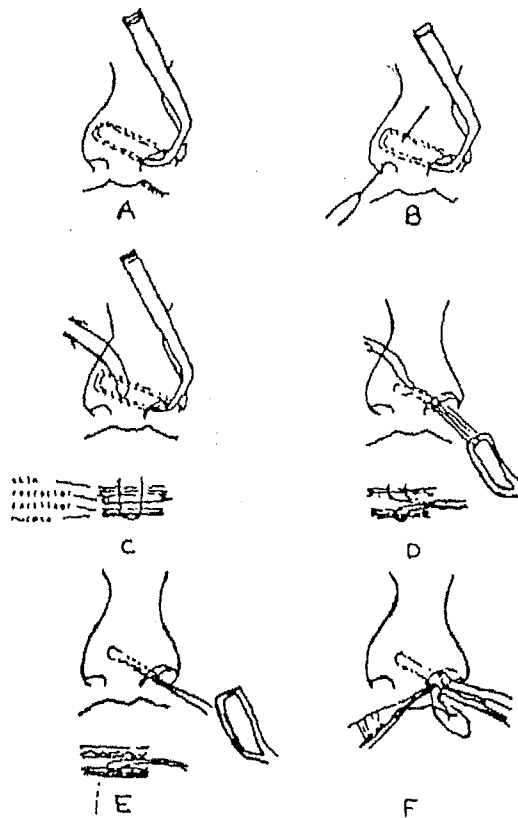


Fig. (26) : The cleft lip nasal retractor placed through the incision (Kernahan et al., 1980).

**Harashina, (1990)** described a modification of Tajima reverse – u incision technique by adding to it the Rethi columella – alar incision described (1919).

The displaced alar base is pushed gently medially and upward with the surgeon's fingers and the reverse-u incision is marked so that the resulting shape of the alar rim become identical with that of the normal side. On the contralateral side the incision a conventional alar rim or marginal incision.

The place where the transverse incision crosses the columella can vary. When there is previous scar on the columella base, it should be used. When there is no much scar, a v-shaped incision is made across the mid-columella. The soft tissue between the medial crura is dissected free as a superiorly pedicle flap. Several 4-0 nylon sutures are placed under direct vision between the abnormal alar cartilage and the opposite alar and upper lateral cartilages and ipsilateral upper lateral cartilage (Fig. 27). After the deformity is adequately corrected, the soft tissue flap is sutured onto the nasal dorsum to help augmentation of nasal dorsum.

Then the columellar flap is returned to its original position and sutured. The reverse-u flap is unfolded by scoring its dermal side with a scalpel.

The excess skin of the flap, if exists, is trimmed and the flap sutured.

The reverse-u flap is compressed with either a bolster suture or an appropriate-sized Nelaton catheter (**Harashina, 1990**).

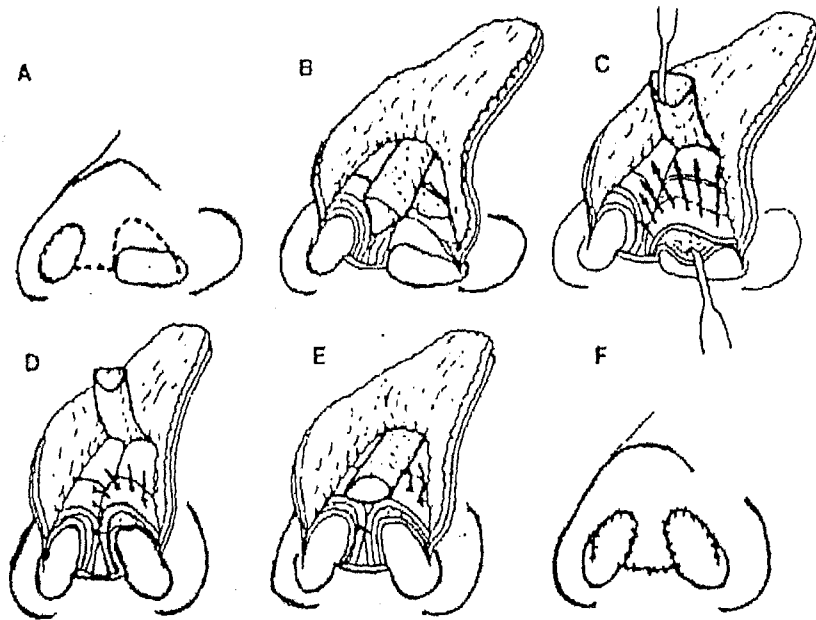


Fig. (27) : Schematic drawing of the open reverse-U incision technique (Harashina, 1990).

Koh K.S. and Eom J.S., (1999) used asymmetric incision for open rhinoplasty in cleft lip nasal deformity.

One of the problems in correction of the unilateral cleft lip nasal deformity is the alar web deformity on the mediosuperior side of the nostril.

A number of methods for correction of the alar web deformity have been introduced, but no single procedure has been identified as the standard.

In this report, the incision line of the open rhinoplasty was modified and alar web deformity was corrected by using an incision and closure.

The incision was different from that of the usual open rhinoplasty in designing the incision line in the cleft side.

Before marking the incision line, the rim of the cleft side was lifted upward with forceps to achieve symmetry of the nasal tip. Then a conventional intranasal rim incision line was marked onto the elevated nostril rim.

After removal of the forceps, the marked line was found to be located on the nasal skin outside the nostril (Fig. 28).

For noncleft side, the incision line was marked in conformity with intranasal rim incision, and the transcolumella incision line completed the asymmetric incision line for the open rhinoplasty.

With this incision, mobilization and suspension of the alar cartilage and interdomal suture of the alar dome were performed under direct view and if necessary, a conchal cartilage onlay graft was added.

**===== Surgical correction of unilateral cleft lip nasal deformities .=====**

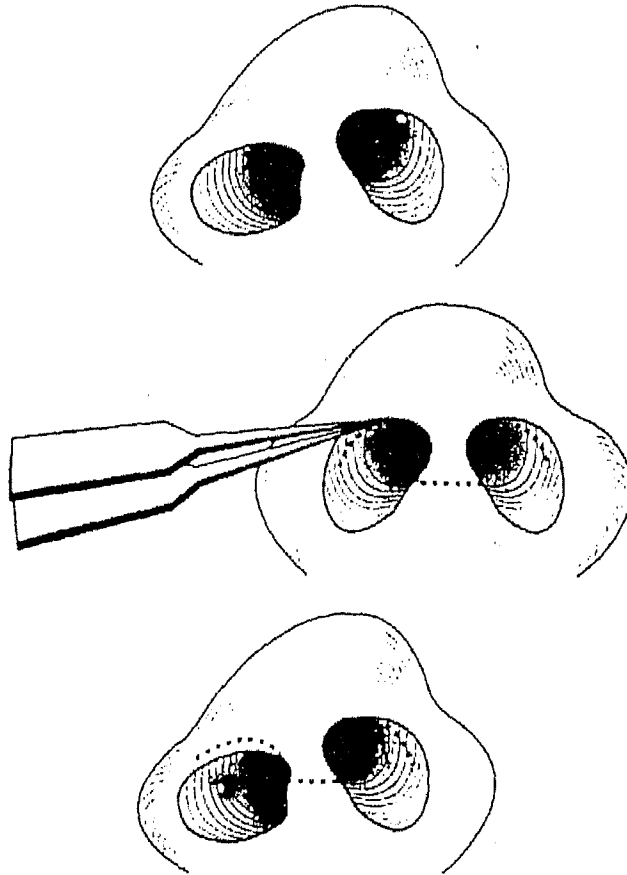
After completion of all procedures, a nasal retainer was applied and each patient was advised to use it for 6 months or more. For children, skin tapes were applied to fix the nasal retainer in position.

The alar web deformity was absent or minimal, and satisfactory symmetry of the nostril was acquired in all patients.

There was no overhanging excess skin in the superomedial nostril rim, and the contour of the alar rim was natural and slender. The stitches in the cleft side shifted into the nasal cavity and were not visible.

This technique resulted in a symmetric shape of the nostrils and disappearance of the alar web.

Post operative follow-up period has been 12 – 26 months and long-term follow-up is necessary especially in growing children (**Koh K.S. and Eom J.S., 1999**).



**Fig. (28) :** (Above) The nose of a patient with unilateral cleft lip. (Center) The incision line is marked as an intranasal rim incision while the nostril of the cleft side is lifted up with forceps to make the nasal tip symmetric. (Below) Note the asymmetric incision line after removing the forceps (Koh K.S. and Eom J.S., 1999).

When the alar cartilages are repositioned. A shortage of skin may become apparent particularly in the alar web and vestibular area. Differences of opinion regarding preservation or excision of the alar-columellar web tissue are apparent in the various approaches recommended.

Alar-columellar web correction by Z plasty was performed as early as 1946 by **Straith** (Fig. 29).

Excision of alar cartilage from the web area and preservation of skin and lining were reported by **Musgrave and Dupertuis, (1960)**; **Millard, (1964a)** and **Salyer, (1986)**.

The principle of conversion of the external skin to nasal lining to correct alar-columellar web has been reported by **Ogino and Ishida, (1980)** and **Millard, (1982)**.

The outcome of **Tajima and Maruyama's** techniques is an excellent nasal contour with minimal external scar and correction of the alar-columellar web.

**Nakajima et al, (1986)** modified the technique by adding a Z plasty in the lateral nasal vestibule (Fig. 30).

Generally, the cleft lip nose has a shortage of nasal lining. The reverse U-flap can add lining tissue to longitudinal dimensions of the nose, but there is still a shortage of lining in the transverse dimension and the tension this causes at the lateral wall of the nasal vestibule produced the plica vestibularis.

As **Ushida, (1971)** described a z-plasty for elimination of the plica vestibularis by combining a reverse – u flap with a z-plasty, recoiling of the flap after its rotation to the desirable position can be prevented.

An added advantage is that the elongated incision permits easier undermining of the nasal skin and suturing of the cartilage (Nakajima et al., 1986).

Additional means to prevent tightness of the vestibular area include various external and internal Z plasties (Trauner, 1956; Stenstrom and Oberg, 1961; Oconnor et al, 1965; Rees, et al, 1966; Maithews, (1968), skin grafts or composite grafts (Fig. 31).

Millard, (1982) rotation advancement flap may have an "L-flap" available for filling in this area.

Long-term correction of the secondary cleft lip nasal deformity depends on an adequate dissection of alar components, the structural integrity of the dissected elements and eventual adherence and growth. Suspension sutures secured to bolsters over the nasal skin or rubber stent catheter can secure the nostril, through and though sutures are an alternative means of support (Jackson L.T. and Fasching M.C., 1990).



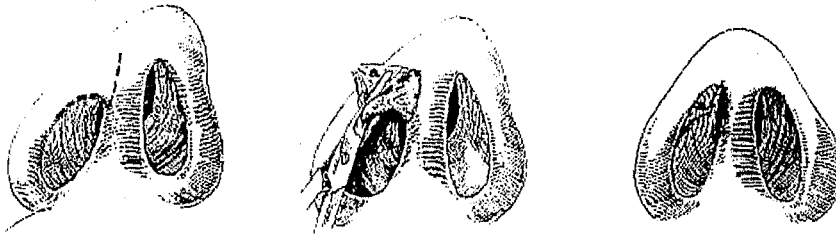


Fig. (29) : Correction of alar-columellar web by modified z-plasty technique (after Straith, 1946) (From Millard Dr. Jr, 1976).

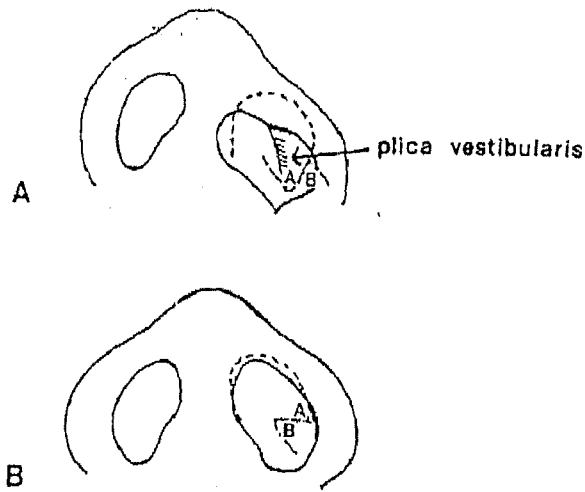


Fig. (30) : The procedure for secondary repair :

A) Design of reverse-u incision + z-plasty.

B) Letter A & B indicate the transposition of flaps of z-plasty.

(Nakajima et al., 1986).

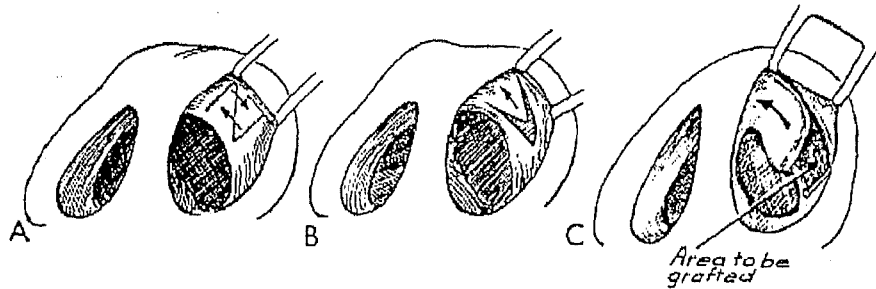


Fig. (31) : Technique for correction of a web in the lateral vestibule :

A) Z-plasty.

B) Y-Y advancement.

C) Medial advancement (arrow) of a medially based flap of vestibular skin and alar cartilage in unilateral cleft lip and nose deformity, a full thickness skin graft is placed in the resulting lateral defect (After Rec et al., 1966).

### **Incision and relocation of alar cartilage :**

There were multiple techniques of incising or splitting of the alar cartilages and subsequent relocation.

**Humby, (1938)** proposed incision and transposition of the upper portion of the unaffected lateral crus across the midline to augment the lateral crus of the cleft side (Fig. 32c).

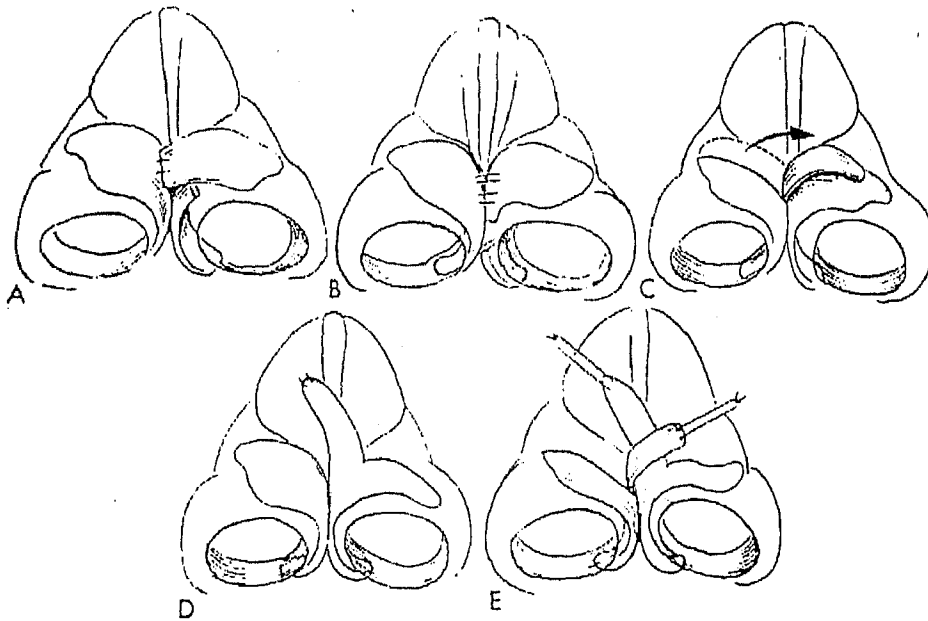
**Brown and McDowell, (1941)** divided the lateral crus and repositioned it across the midline over its own medial crus and dome. It was suspended to the contra lateral dome through an intranasal incision (Fig. 32a).

**Barsky, (1950)** relocated and suspended the cephalic border of the lateral crus on the cleft side to the dorsum of the septum using an external incision (Fig. 32d).

**Erich, (1953)** divided the medial crus on the cleft side through an external incision and suspended the dome area to the contralateral dome (Fig. 32b).

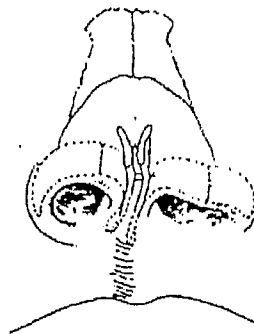
**Whitlow and Constable, (1973)** used a figi-type external incision and described a technique of crossed bilateral alar winged flaps suspended through the skin by pull-out bolster sutures (Fig. 32e).

**Kazanjian, (1939)** described elevation of the medial crura of both alar cartilages as medially based flaps, these are sutured together vertically after division from the lateral crus. Excision of alar base wedges and semilunar excision of skin from the alar area also modified nostril width and projection (Fig. 33).



**Fig. (32) : Relocation of the alar cartilages :**  
A) The Brown and McDowell Technique (1941).  
B) The Erich Technique (1953).  
C) The Humby Technique (1938).  
D) The Barsky's Technique (1950).  
E) The Whitlow Technique (1973).

(From Converse J. M. et al., 1977)



**Fig. (33) Kazanjian, 1939**

The hinged cartilage flaps depend on preservation of cartilage integrity to maintain the elevation and the position of the remaining alar cartilage. Pre-requisites are a strong, well developed cartilaginous component that can withstand the stresses necessary to move attached soft tissue. Since the cartilage of the alar dome is frequently thin and fragile, construction of a durable tip may not be possible without the addition of a cartilage graft (Jackson L.T. and Fasching M.C., 1990).

### **Graft augmentation :**

If adequate and symmetric nasal projection is not obtained by suspension and repositioning of the alar cartilages, it can be achieved by cartilage graft augmentation of the cleft ala.

**Lamont, (1945)** harvested the cephalic margin of the uninvolved ala to augment the cleft alar dome (Fig. 34a).

**Fomen et al., (1956)** placed ear cartilage grafts over the lateral crus in the columella and anterior nasal spine (Fig. 34b).

**Musgrave and Dupertuis, (1960)** advocated a sutured multitiered cartilage graft (Fig. 34c).

**Millard, (1964b)** was proposed a columellar strut graft of the septal cartilage to increase nasal tip projection (Fig. 34e).

**Gorney and Falces, (1973)** used a "gull-wing" conchal graft. This was formed by suturing conchal graft together with their concavities opposing one another (Fig. 34f).

**Dibbell, (1976)** and **Chiat, (1981)** shaped costal cartilage into a "bowie-knife" strut for placement in a pocket created in the columella and the membranous septum. Support of the nasal tip by positioning with the

concave portion turned cephalically provided a graceful slope for the nasal dorsum and supra tip area (Fig. 34 h,i).

Augmentation of the columella and the tip can be achieved satisfactory by the “Minerava’s helmet” or lily conchal cartilage graft (**Tessier and associates, 1969**) (Fig. 34g).

**Pollet, (1972)** used a C-shaped costal cartilage graft for tip projection. It is inserted through an incision in the columellar rim, which extends into the floor of the nose. The graft provides support for the depressed ala and augments the nasal sill in addition to its effect on the nasal tip. It is placed superficial to alar cartilage and is secured to the medial crura of both alar cartilages (Fig. 34g).

**Thomson, (1985)** described an incision of the alar rim to produce a medially based flap. Interposition of the alar rim flap resulted in lengthening of the columella. The nasal tip and perialar sulcus are augmented with a conchal cartilage graft (Fig. 34j).

The long-term maintenance of the graft dimension and position in adult and adolescents has been reasonably well documented by **Millard, (1976)** and **Ortiz-Monasterio and Olmedo, (1981)**.

The long-term fate of grafts used at the time of primary procedures has not been well studied with respect to longitudinal growth.

Cartilaginous columellar grafts must be sufficiently rigid to produce projection and shaping of the soft tissue. Subsequently, they may cause distortion or displacement of the nasal tip owing to warping (**Jackson L.T. and Fasching M.C., 1990**).

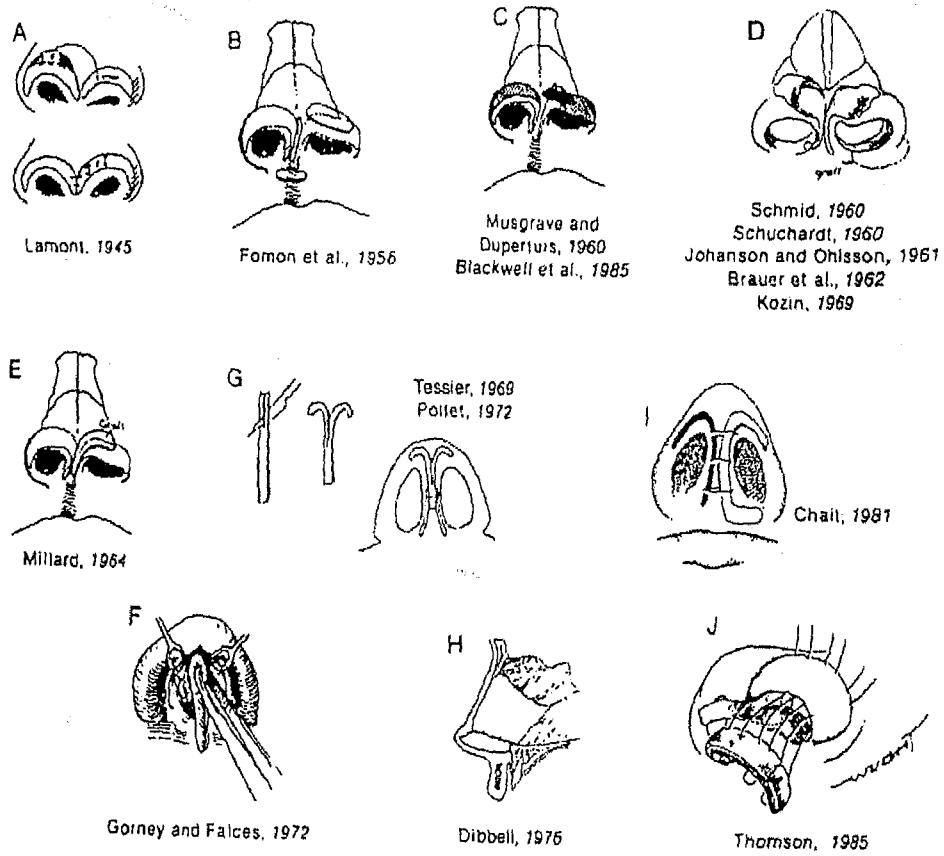


Fig. (34) : Correction of nasal tip deformity using a selection of cartilage grafts.  
(Jackson, L.T. and Fasching M.C., 1990)

Alloplastic support for columella (e.g. silicone) should not be used because the frequent occurrence of erosion through the skin (Millard, 1976). This complication may also occur with costal cartilage grafts (Rohrich and Tebbetts, 1987).

Grafts of cartilage on bone have also been used to elevate and support the displaced alar base and nostril sill (Hugo and Tumbusch, 1971; Schwenger, 1973). Dermal fat grafts (Cosman and Crikelair, 1965) proplast. Jackson, (1984) have also been used to augment the hypoplastic maxilla and overlying alar base.

Foreign body implants (e.g. proplast and hypoxyapatite) are used only when an extremely watertight closure of the mucosa is obtained and haematoma can be avoided. In some severe nasal deformities, it may be necessary to insert cartilage or bone grafts to establish a new nasal dorsum and to obtain satisfactory tip projection (Jackson L.T. and Fasching M.C., 1990).

Dibbell, (1982) published a unique approach utilizing an external incision and excision of the tip skin that addresses the deformities of the unilateral cleft lip nose and of major importance, changes the long axis of the cleft nostril (Fig. 35).

It builds upon the basic concepts of the Blair, (1925) alar rotation and Cronin (1958) columella lengthening procedure for bilateral cleft lip nose deformity. With this procedure there is complete release of the cleft side of the nose. Essentially the entire nostril is freed including the alar cartilage and is rotated as a "sock" or "sleeve" into its new location.



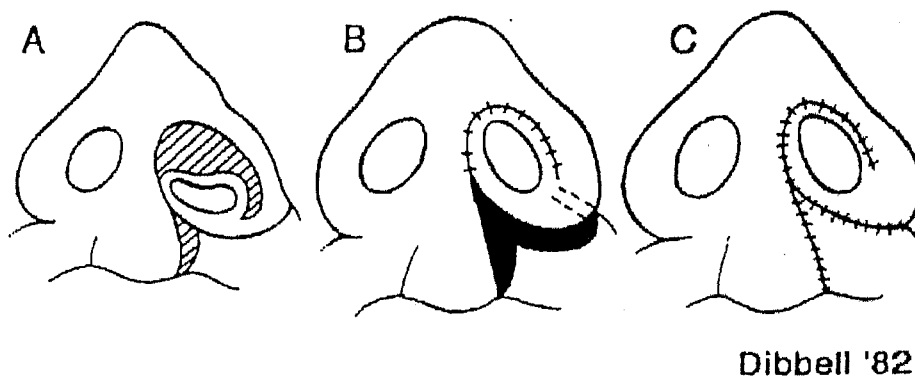


Fig. (35) : A) A deformed crescent moon-shaped area of skin is excised and incision extend around the ala. B) Nostril completely freed and rotated into position. A wedge of lip removed to facilitate advancement of the cheek and lip. C) The completed product (Dibbell, 1982).

The incision is designed to match the noncleft side and a deformed crescent moon of the skin above the cleft nostril is removed.

The incision then extends inferiorly down the margin of the columella across the vestibule just inferior to the nasal sill and around the ala. The skin over the nasal tip is freed and a pocket created for rotation of the underlying cartilage-nostril complex.

A permanent suture may be placed from the new dome to the opposite alar cartilage and/or the opposite upper lateral cartilage to hold the rotated nostril in place. A second mattress suture is placed over a bolster to hold the lateral ala in its new position. A wedge of cleft side lip tissue may be removed to allow the cheek to move medially to fill the space vacated by the cleft nostril.

**Connelly M.V., (1993)** combine the advantages of the Dibbell procedure with that of the external approach rhinoplasty popularized by **Goodman and Zorn, (1982)**.

The advantages of the combined approach include :

- a) Exposure of the cartilaginous structures without distortion.
- b) Removal of the edge of the alar rim matching the noncleft side.
- c) Complete freeing of the cleft nostril from the piriform aperture with rotation into a symmetric position.
- d) Lengthening of the columella on the cleft side.
- e) Exact placement of permanent sutures.
- f) Direct application of only cartilage grafts, if needed.
- g) Correction of associated lip deformities and,

h) Excellent exposure for septoplasty and/or bony work.

They have been using this combined approach incision for the majority of unilateral revisions for the past 7 years.

General anesthesia is used in all patients.

The amount of local anesthetic with epinephrine used in the tip area is kept to a minimum.

The incision is outlined as shown in (Fig. 36).

A crescent moon-shaped piece of alar tip skin is marked for excision. The incision on the cleft side continues inferiorly along the face of the columella about 2mm from the edge. It extends around just inferior to the nasal sill sweeping laterally into the alar-facial groove.

This incision on the cleft side joins a standard external incision on the noncleft side with the typical inverted V. The entire nostril is freed widely from the noncleft medial crus, septum, floor of the nose, lip and piriform aperture. It may be necessary to incise through mucous membrane to allow for complete freedom of rotation. The nasal skin is elevated as far superiorly toward the nasion and laterally over the alar cartilages as possible, to provide enough exposure. Once rotated into position the nostril should sit freely without any tugging on adjacent tissues.

The rotation of the nostril brings the lower lateral cartilage into its normal position, lengthens the cleft side columella, and should create a symmetric tip. The new position of the nostril is maintained with permanent sutures from the cleft ala to the noncleft upper lateral cartilage. Other deep sutures are placed as necessary.

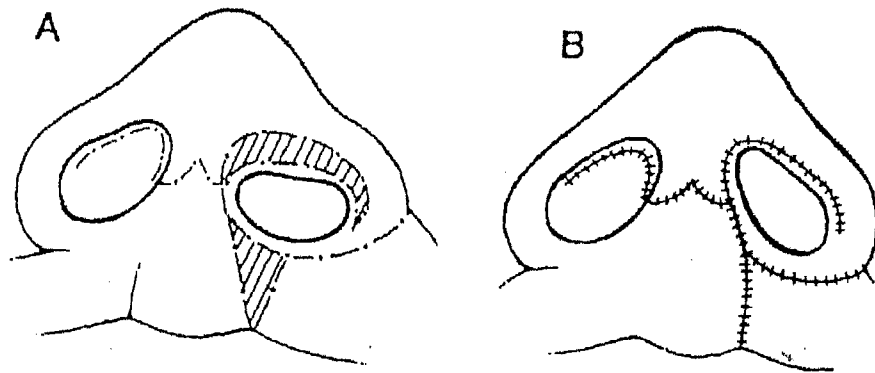


Fig. (36) : A) Typical external approach rhinoplasty incision combined with the Dibbell incision. B) Completed incisions (Connelly M.V., 1991)

Most of the time, a cartilage strut is placed between the medial crura and suture to them with several sutures (Dibbell D.G., 1976). The strut should extend from the level of the anterior nasal spine to just inferior to the nasal domes. A longer strut may produce a visible tenting beneath the tip skin.

Occasionally it may be necessary to completely free the lower lateral cartilage on the cleft side from its attachment to the vestibular skin in order for it to move to its normal position. If this is necessary then a permanent 5-0 nylon mattress suture gathering lateral - medial - medial - lateral cartilage and back after the technique of McCollough and English, (1985) is often used. Further only septal or auricular cartilage graft may be applied as needed (Sheen J.H., 1978).

Because the nostril move medially as well as superiorly, the cheek must be advanced; thus the need for excision of a wedge of lip tissue inferiorly to the vermilion cutaneous junction in some cases. However, in a number of patients revision of the lip scar is needed anyway. If the above procedure is done on a child, then the skin is redraped and the columella closed with 6-0 black nylon. The intranasal incisions are closed with 5-0 chromic. The nose is taped and a cast applied and the nostril filled with cellulose cotton.

The cast is removed along with sutures and packing under a short general anesthesia in 5 to 7 days in children.

Adolescents are cared for in the office as with any other adult.

If tip rhinoplasty is being combined with septorhinoplasty, they like to perform septoplasty after all of the tip work has been completed but before permanent sutures have been placed (Connelly M.V., 1993).

Rifley and Thaller, (1996) found that it is extremely helpful to do an open approach in the definitive correction of the cleft nasal deformity depending on the previously placed incisions, they were generally employ a transcolumellar stair-step type incision placed with the narrowest position on the columella (Fig. 37).

Then, it was carried into a standard lateral marginal incision. At this point, a typical open rhinoplasty dissection was continued, exposing the underlying nasal anatomy.

The affected ala was the most common abnormality encountered and, unfortunately, was often the most difficult for achieving a satisfactory functional and aesthetic result.

In those cases, in which there was sufficient lining, they were mobilize the alar-nostril unit from the maxilla to achieve medial and anterior repositioning, allowing derotation of the tilted tripod with a suspension technique, they were then able to reposition the separated and dislocated ala. This technique, which was not new, has evolved from a simple ipsilateral lower to upper suture suspension to horizontal mattress suture that redirects the alar cartilage with a rector that crosses the midline to the contralateral upper and lower lateral cartilage (Fig. 38).

If suture techniques fail to achieve the desired symmetry, then they perform cartilaginous augmentation of the hypoplastic lower lateral cartilage. In their experience, this has been the rule rather than the exception in cleft patients.

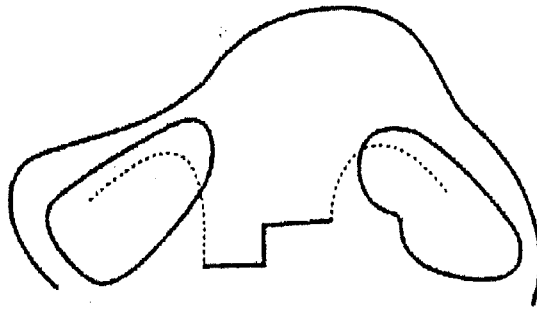
Their preference was conchal cartilage for repair of the lower lateral cartilage, the graft was shaped and secured with nonabsorbable suture to the ala often, a cartilaginous strut was also necessary to obtain sufficient support (Fig. 39).

A combined columella strut-alar augmentation graft can be fashioned similar to techniques previously reported by Millard and Tessier. Tip projection was generally achieved by a modified tip onlay graft.

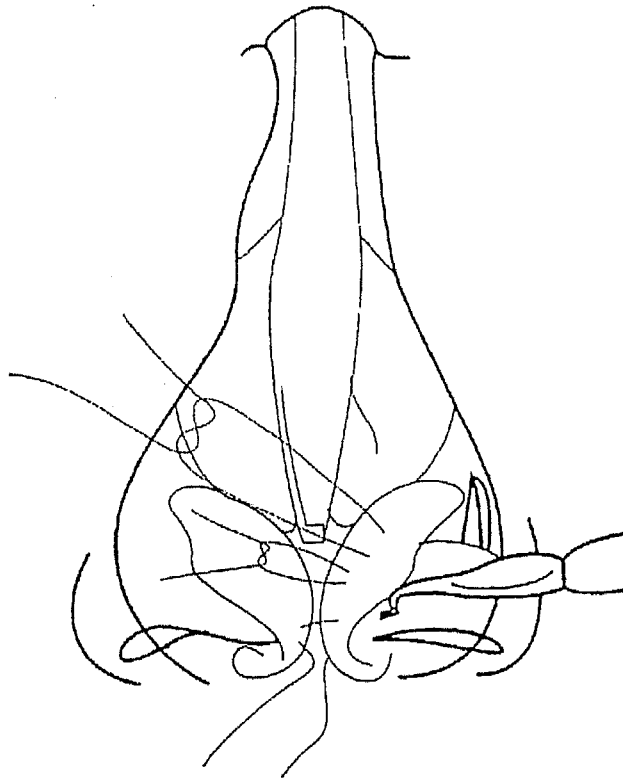
A short columella significantly restricts tip projection and usually the result of an underdeveloped ipsilateral lower lateral cartilage and deficient soft tissue.

**Cronin, (1958)** provides a well written review of various techniques employed to lengthen a short columella. The number of previous articles attest to the difficulty in obtaining consistent excellent results.

If nasal lining was deficient, secondary to either scar contraction or intrinsic process, they correct this shortage of vestibular lining at the time of repair depending on the underlying pathology, they employ either Z-plasty or V-Y advancement or bring in new lining with a skin or composite graft (**Riffey and Thaller, 1996**).



**Fig. (37) :** Open approach using a staggered columella incision placed at the narrowest point (Rifley and Thaller, 1996)



**Fig. (38) :** Horizontal mattress suture suspension of involved lower lateral cartilage to contralateral upper and lower cartilage (Rifley and Thaller, 1996)



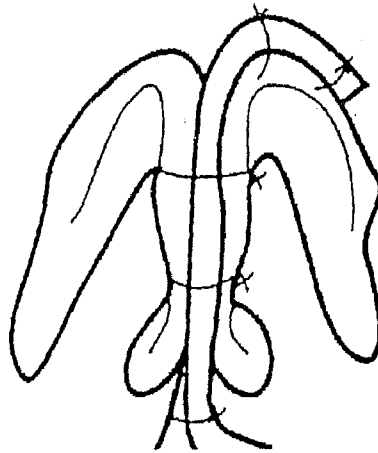


Fig. (39) : Combined columella strut alar augmentation graft (Rifley and Thaller, 1996)

Nakajima T. and Yoshimura Y., (1998) present approach for secondary repair of unilateral cleft lip nose deformity with bilateral reverse-U access incision.

***Surgical Procedure :***

Through bilateral reverse-U incisions, the alar and lateral cartilages are undermined subcutaneously. To acquire normal nasal tip projection, the areolar tissue between the alar cartilages elevated with the dorsal skin and used as augmentation material after suturing the cartilage (Fig. 40).

Through the bilateral reverse-U incisions, the deformed cartilages are clearly seen and sutured under vision. To make a well defined alar groove and nasal bridge, an inverted trapezoid suture is placed from the alar cartilage to the alar groove. Two or three additional box sutures of 3-0 absorbable monofilament (Maxon) are placed subcutaneously over the nasal dorsum. The knot of the suture is buried through a stab incision (Fig. 41).

To prevent postoperative recurrence of the deformity, the alar cartilage of the cleft side is elevated slightly more than non cleft side. At the end of the operation, a long retainer is inserted into the nostrils and fixed against the two rows of rolled gauze blisters fixed over the nasal dorsum. This fixation is maintained for 1 week after surgery after removal of the suture fixation, the retainer is kept in place for 1 or 2 months after surgery to prevent recurrence of the nasal deformity.

In this method, the columella is not transected, so the anatomical point of columello-labial angle is not lost, even after correction of the alar cartilages. In addition, the scar of the insertion is completely hidden inside the nostril.

For secondary repair of unilateral cleft lip nose deformity, a bilateral reverse U incision combined with an inverted trapezoid suture is an excellent method to attain nasal symmetry (Nakajima T. and Yoshimura Y., 1998).

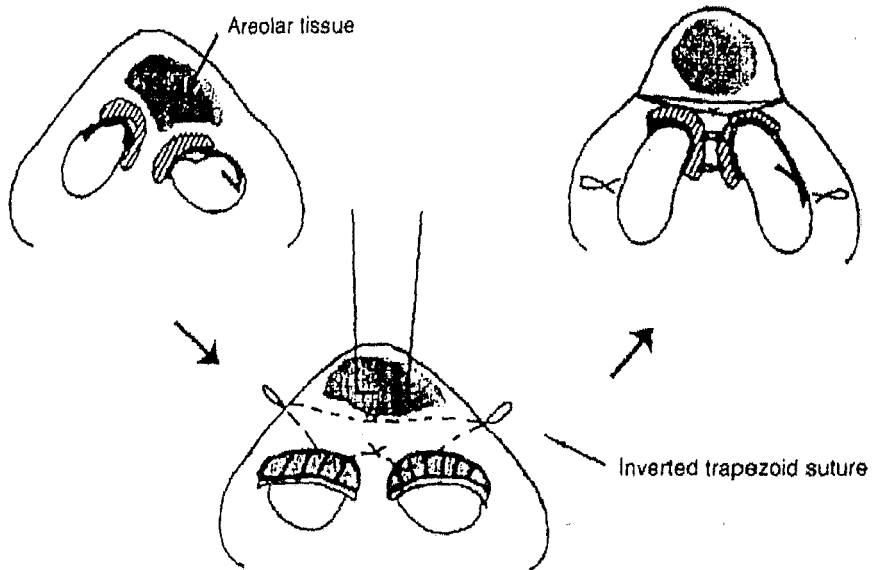


Fig. (40) : A schematic drawing of the operative procedure (Nakajima T. and Yoshimura Y., (1998).

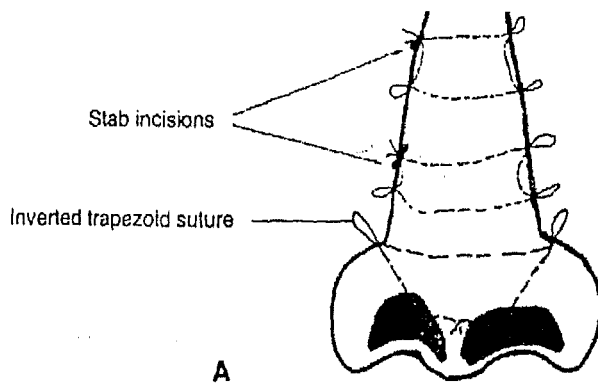


Fig. (41) : Placement of buried sutures (Nakajima T. and Yoshimura Y., (1998).

Uhm K.I. et al., (2000) use the calvarial bone graft and suture suspension in oriental patients.

Compared with Caucasians, oriental people have under developed, thin cartilage and thick skin in the lower half of the nose.

To correct asymmetries of the nostrils in cleft lip nose deformities in Orientals, the alar cartilage mobilization and suspension technique is the most suitable.

However, insufficient lifting of the alar cartilages and relapse are problems that have not been corrected using conventional methods.

The correction requires a stiff supporting framework to use suspension sutures for the deformed alar cartilage. They used the cantilever calvarial bone graft on the nose for this purpose (Fig. 42).

In the past 3 years, they treated 30 oriental patients with cleft lip nasal deformity using the combined procedures of only calvarial bone grafting and alar cartilage suture suspension.

This combined procedure provides a sufficient lift to the alar cartilage, projection of the nasal tip, and correct plica vestibularis.

In their follow-up, no remarkable relapse of the corrected alar cartilage occurred, and nostril symmetry has been maintained.

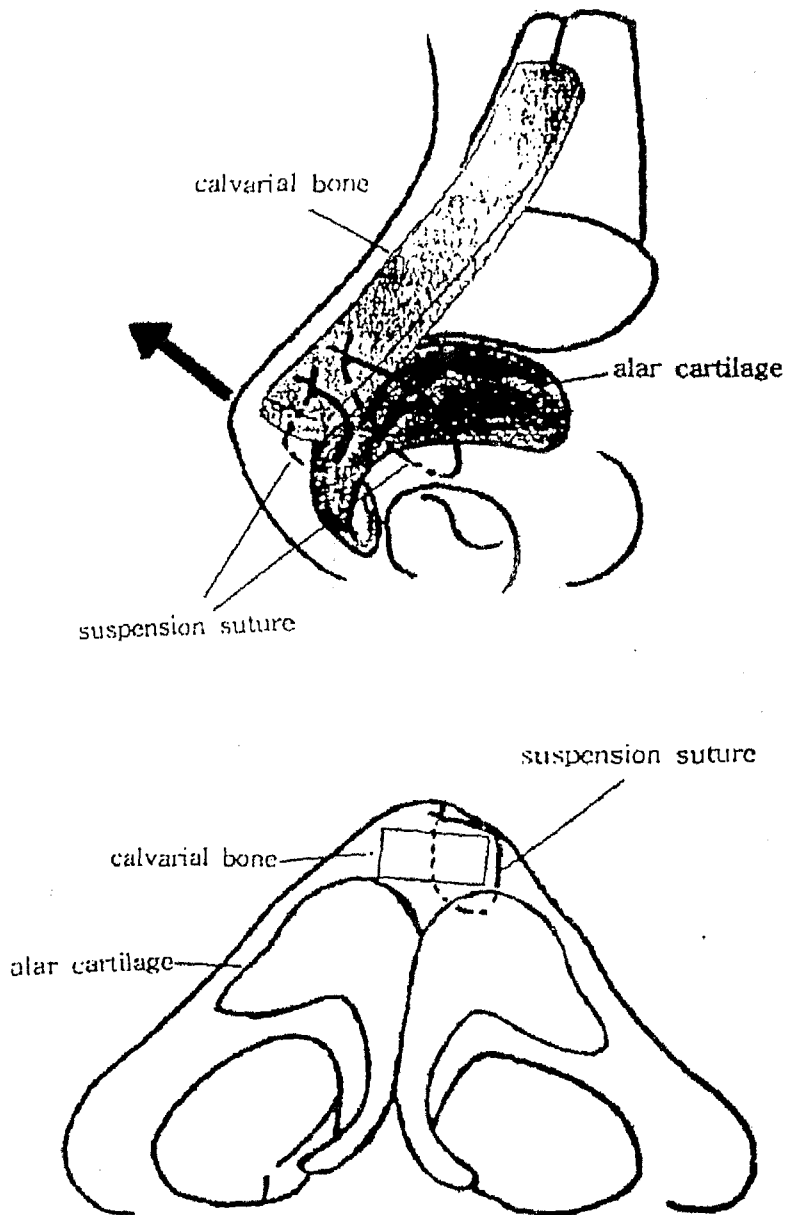


Fig. (42) : The fixed calvarial bone acts as a framework for suture suspension of the deformed alar cartilage and elevates the depressed dorsum nasi. Two holding sutures from the calvarial bone graft were sutured to the intercrural angle of the flared lateral crus of the alar cartilage on the cleft side and the vestibular web (Ki IL Uhm, 2000).

*PATIENTS  
AND  
METHODS*

## **PATIENTS AND METHODS**

This study included twenty patients with unilateral cleft lip nasal deformity who presented to children's hospital Cairo University during the period from October 1999 to October 2000. Their ages ranged between 8 months to 12 years.

In a randomized double blind study, the twenty cases were divided into two group :

Group (A) : Included (5) patients that had a primary rhinoplasty at the time of lip repair.

Group (B) : Included (15) patients were repaired by secondary rhinoplasty after the lip repair was done. This group was further subdivided into :

- Group (B1) : Alar deformity is the main symptoms (14) cases.
- Group (B2) : Short and deviated columella (4 cases).
- Group (B3) : Alar web deformity (4 cases).

**They were assisted clinically as regard :**

### **A) History :**

Detailed history was taken as regards to :

1. Personal history : name, age, address, .... etc.
2. Complain of parents such as difficult suckling in primary cases and nasal deformities in secondary cases.
3. Family history : parent consanguinity, similar condition in the family ... etc.
4. Present history : presence of associated conditions e.g. cleft palate .... etc.

## **B) Clinical examination :**

### **1. General examination :**

- State of nutrition.
- Associated anomalies such as cleft palate, syndactyly .... etc.
- Other diseases such as cardiac, respiratory, renal, hepatic diseases.

### **2. Local examination :**

#### *A) In primary cases :*

- Type of cleft lip : unilateral or bilateral Rt or Lt, complete or incomplete.
- State of alar cartilage : buckling, splaying ... etc.
- State of columella → short, deviated ... etc.
- Other associated local anomalies.

#### *B) In secondary cases :*

- State of the lip repair :
- Time of lip repair
  - Method of lip repair.
  - Presence of deformities after lip repair.

- State of nose :
- Alar cartilage : buckling, splayed.
  - Columella : short, deviated.
  - Alar web, present, absent.
  - Nasal floor deficiency.

## **Investigation :**

Complete blood picture was done to every case, bleeding time, clotting time.

Patient were admitted to the hospital on the day of operation fasting for 4 – 6 hours prior to operation.



Patients were admitted for 24 hours to watch for any complications e.g. respiratory complication, bleeding .... etc.

### **Operative techniques :**

**Anaesthesia :** General endotracheal intubation with Raye's tube.

**Position :** Supine..

#### **Marking of incision :**

The rim of the cleft side was lifted upward with forceps to achieve symmetry of the nasal tip, then with the use of marking pen, a v-shaped transcolumellar incision at the level of mid columella (midway between tip of nostril and base of columella) was marked, then a bilateral intranasal rim incision was marked onto the elevated nostril (Fig. 28).

In group (A) the points of rotation advancement repair were marked. These nine points included peak of Cupid's bow on the normal side (point 2), low point of Cupid's bow (point 1) proposed peak on the cleft side was marked (point 3), mid point of the columella was marked (point 4) the lateral base of columella was marked (point 5, 6) alar base on the cleft and non cleft side was marked (point 7, 8) and the proposed peak of Cupid's bow on the lateral element of cleft was marked point (9) (Fig. 43).

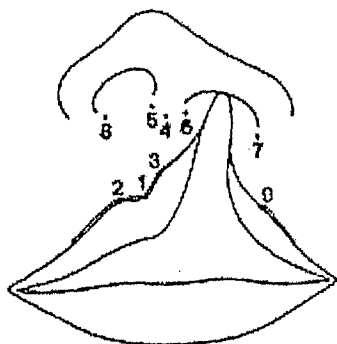


Fig. (43) : Key points used for planning repair.

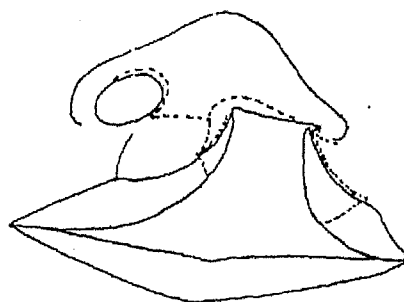


Fig. (44) : Preoperative marking for unilateral cleft lip repair with open tip rhinoplasty.

**Haemostasis :** was done by the use of solution of adrenalin – saline 1/200000 dilution was injected into subcutaneous tissue in the nasal tip and vestibular skin.

**Incision :** by using a no 11 blade we follow the mid columellar V-shaped marking to complete mid columellar incision, the blade was kept perpendicular the skin, therapy preventing beveling of the skin edge. Then by the use of no 15 blade the marginal rim incision marking was completed beginning laterally making a light incision through the vestibular skin 1 – 2 mm caudal to the caudal margin of the lateral crus as the incision extended medially.

**In group (A) primary cases :**

- The attachment of the lip to the underlying alveolar border were freed using the bovie. Then by using no 11 blade, the edges of the cleft lip were freshened in a through and through fashion.
- The rotation flap was first incised using the same blade, the curved incision extended from the height of Cupid's bow on the cleft side to the mid columella this stab incision extended parallel and medial to the philtral margin of the cleft side. Then the advancement flap was incised in the same fashion.

**Dissection :**

Using the angled converse scissors we elevated the thin vestibular skin of the flap that covers the medial crura, then the scissors was inserted beneath the columellar extension of the marginal incision and dissect medially below musculoapneurotic layer, the scissors was passed superficial to the caudal margin of the both medial crus. Then by the use of converse scissors the midcolumellar incision was completed, we used a

narrow double hook to retract the flap. The paired columellar arteries may be seen and was cauterized with bipolar cautery.

To elevate the skin and soft tissue envelope over the nasal tip we were place a wide double hook along the margin of nostril rim caudal to the lateral crus, place a small double hook on the columellar flap and small double hood was placed on the vestibular skin, then we used the converse scissors to dissect the columellar flap from the caudal margin of the medial and intermediate crus, then the scissors was used to expose the caudal aspect of the lateral crus as well the soft tissue was elevated, leaving only the perichondrium on the cartilage, a cotton tip applicator was used to complete dissection over the lateral crus and this maneuver was repeated on the opposite side.

Then the midline dorsal dissection was done by division of fibrous connections in the midline near the surface of the dome to release the flap and allow dissection cranially, we was use a cotton tip applicator to dissect bluntly the soft tissue envelope cranially and laterally till the upper lateral cartilage was exposed.

### **Skeletonization of the cartilage :**

To correct the alar deformity we skeletonized of the cartilage by using three stitches the first was midline approximation of the dome of the normal alar carilage to the splayed dome of the deformed side (interdomal stitch). The second was attaching the highest point of the lateral crus of deformed cartilage to the upper lateral cartilage of the same side (ipsilateral upper lateral cartilage). The third stitch was attaching the lateral crus of the deformed side to the upper lateral cartilage of the opposite side (contralateral upper lateral cartilage).

*Suture material* : used was prolene 5/0.

*Skin closure* was done by use of vicryl 5/0 or prolene 5/0 and columellar flap was closed in v-y fashion so as to add length to columella → (columellar lengthening).

We used z-plasty at the lateral end of the rim incision to correct the alar base webbing when present.

*In group (A) primary cases* :

- The skin of both flaps were raised off the orbicularis muscle using sharp dissection.
- Then the muscle was closed using interrupted 4/0 vicryl, several anchoring stitches were taken in the skin to assume the final shape of the lip using 5/0 vicryl.

**Dressing :**

- In group (A) primary cases : Immediately after operation antibiotic ointment was applied to the suture line of the lip and nose followed by compression with gauze for haemostasis and gauze was removed 6 hours later and wound lifted exposed and antibiotic ointment was applied 4 times daily.
- In group (B) secondary cases : Antibiotic ointment was applied to the suture line of the nose then vasline gauze pack was applied to the nose and removed in the second postoperative day and antibiotic ointment was applied to the wound 4 time daily.

### **Medical treatment :**

The following drug was used for all patients postoperatively :

1. Broad spectrum antibiotics : Ampicillin in a dose of 50 – 100 mg/kg/day for 10 days.
2. Topical antibiotic : topical ointment was applied every 6 hours.

### **Follow up of the cases :**

The patient were followed up in the outpatient clinic and take photographic documentation as follow :

1. Patient in group (A) (primary cases) was discharged in the second postoperative day and on group B (secondary cases) was discharged on the fifth postoperative day.

2. The patients were examined in the outpatient clinic every week during first month and every two weeks for next 6 months.

3. The items of assessment include :

a) Degree of postoperative oedema :

- Mild oedema : if took less than 3 days to subside.
- Moderate oedema : if took more than 3 days and less than week to subside.
- Severe oedema : if took more than 1 week to subside.

b) Presence of complication e.g. haemorrhage, infection, oedema, trauma.

c) State of deformity.

d) Evaluation of the late results : 3 – 6 months postoperatively by assessing the cosmetic appearance of nasal tip, columella, alar webbing.

# ***RESULTS***

## RESULTS

This study has been conducted in the pediatric surgical department of the new children's hospital Cairo University.

The study included twenty patients suffering from unilateral cleft lip nasal deformities.

They were divided into two groups :

1. **Group (A)** : primary rhinoplasty was done.
2. **Group (B)** : Secondary rhinoplasty was done.

### Distribution of the studied cases according to their ages :

The age of the patients in group (A) ranged between 6 months to 12 months with mean age 9 months.

The age of the patients in group (B) ranged between 2 years to 12 years with mean age 7 years.

Age group	< 2 year	2 - 6 year	> 6 year	Total
Group (A)	5	0	0	5
Group (B)	0	12	3	15

**Table (1)** : Shows the age distribution of the studied cases.

- **Distribution of the studied cases according to sex :**

Sex of patients	Male	Female	Total
Group (A)	3 60%	2 40%	5 100%
Group (B)	9 60%	6 40%	15 100%

**Table (2) :** Shows that the sex of the patients in both group was male > female.

- **Distribution of the studied cases according to the time of lip repair :**

Age group in months	< 4	4 – 8	> 8	Total
Group (A)	- %	3 60%	2 40%	5 100%
Group (B)	6 40%	6 40%	3 20%	15 100%

**Table (3) :** Shows that in the majority of cases in both group the lip repair was done < 8 months.



- **Distribution of the studied cases according to the method of lip repair :**

**In group (A) :** In all patients Millard rotation-advancement was done.

**In group (B) :** In 6 patients Tennison repair was done while in 9 patients Millard's repair was done.

- **Distribution of the studied cases according to the time of nasal repair :**

**In group (A) :** The nasal repair was done at the time of lip repair (primary rhinoplasty) between the age of 6 months to 12 months with mean ages of 9 months .

**In group (B) :** The nasal repair (secondary rhinoplasty) was done between the age of 2 - 12 years with mean ages of 7 years.

- **Distribution of the studied cases according to the nasal deformities :**

Nasal deformities	Alar cartilage deformities	Columellar deformity	Alar webbing
Group (A)	5	-	-
Group (B)	14	4	4

**Table (4) :** Shows that :

- The alar cartilage deformities was present in all cases of group (A) while in group (B) 14 patients had alar cartilages deformities.
- Columellar deformities was present in 4 patients in group (B).
- Alar webbing was present in 4 patients in group (B).

It was difficult to assess the results of our patients especially there is no solid parameters to consider it as a reference for assessment of the repair. However, we depended upon comparison of the contralateral nostril, judgement of surgeons, acceptance of the parents and data measures (hemicolumellar height, alar webbing, nasal floor deficiency and bifidity of alar cartilage). We advocated a simple ascoring system for the judgement of the results and compared to contralateral side and using photographic documentations.

**Table (5) : Scoring system for assessment of results :**

Score	3	2	1
Hemicolumellar height	80 – 100%	60 – 80%	< 60%
Alar webbing	Absent	Minimal	Present
Nasal floor deficiency	Absent	Minimal	Present
Nasal bifidity	Absent	Minimal	Present

If the patient had a scoring from 9 to 12 the result was considered good, if the scoring from 6 – 9 the result was considered fair and scoring < 6 the result was considered poor.

- Distribution of the studied cases according to the results of the operative technique

Results	Group (A)		Group (B)	
	No	%	No	%
Good	4	80%	12	80%
Fair	1	20%	2	13%
Poor	-	-	1	7%

**Table (6) :** Show that :

- The overall results of the repaired cases in group (A) (primary rhinoplasty).
- Good results occurred in 4 cases 80%.
- Fair results occur in 1 case (20%).

The overall results of the repaired cases in group (B) (secondary rhinoplasty).

- Good results in 12 cases 80%.
- Fair result in 2 cases 13%.
- Poor results in 1 case in which major complication occur postoperatively dehiscence of the wound occur.

- Distribution of the studied cases according to postoperative morbidity :

Results	Group (A)		Group (B)	
	No	%	No	%
Haemorrhage 1ry	1	20%	0	0%
Oedema	2	40%	3	20%
Wound infection	0	0%	0	0%
Trauma (dehescence of wound)	0	0%	1	1%

Table (7) : Show that :

- In group (A) morbidity of the studied cases (temporary complications) that required no further surgery were encountered in 3 cases :
  - Primary haemorrhage in the first day postoperatively that was controlled by compression occur in one case 20%.
  - Mild oedema of the wound occurred in two cases 40% which subside spontaneously by the end of the first week postoperatively.
- In group (B) : Temporary complications were encountered in 3 cases 20%.
  - Mild oedema of the wound were occur in 3 cases (20%) which was subside by the end of the first week postoperatively.
  - Major complications was encountered in one case (7%) in which trauma to the wound was occurred lead to complete dehiscence of the wound.

Table (8) : Distribution of the studied cases according to the overall results.

Case No.	Age	Sex	Time of lip repair	Method of lip repair	2ry lip deformities	Nasal deformities	Method of correction	Complications	Results
1	6 m.	M	5 m.	Millard	-	Buckling, splaying of alar cartilage. Deviated columella. Flattened alar-facial angle and widened of alar base.	Millard repair and open tip rhinoplasty	-	Satisfactory
2	8 m.	F	8 m.	Millard	-	Buckling, splaying of alar cartilage. Widened of alar base.	Millard repair and open tip rhinoplasty	Oedema	Satisfactory
3	12 m.	M	12 m.	Millard	-	Splayed alar cartilage. Widened of alar base. Deficient nasal floor.	Millard repair and open tip rhinoplasty	Oedema	Fair
4	12 m.	M	12 m.	Millard	-	Splayed alar cartilage. Widened of alar base. Deficient nasal floor.	Millard repair and open tip rhinoplasty	Haemorrhage	Satisfactory
5	6 m.	F	6 m.	Millard	-	Buckling of alar cartilage. Widened of alar base. Deficient nasal floor.	Millard repair and open tip rhinoplasty	-	Satisfactory
6	5 y.	F	3 m.	Millard	-	Buckling of alar cartilage. alar webbing.	Open tip rhinoplasty. Z-plasty.	-	Satisfactory
7	8 y.	M	6 m.	Millard	-	Buckling and splaying of the alar cartilage. Flattened nasal tip.	Open tip rhinoplasty	Postoperative trauma	Poor
8	6 y.	M	3 m.	Millard	-	Buckling and splaying of the alar cartilage. Deviated, short columella.	Open tip rhinoplasty v-y plasty	-	Satisfactory
9	5 y.	M	5 m.	Millard	-	Buckling and splaying of the alar cartilage.	Open tip rhinoplasty	Oedema	Fair
10	2 y.	F	3 m.	Tennison	-	Buckling and splaying of the alar cartilage. Widened of alar base.	Open tip rhinoplasty	-	Satisfactory

Table (8) : Cont.

Case No.	Age	Sex	Time of lip repair	Method of lip repair	2ry lip deformities	Nasal deformities	Method of correction	Complications	Results
11	6 y.	M	4 m.	Tennison	-	Buckling, splaying of alar cartilage. Deviated columella.	Open tip rhinoplasty	-	Satisfactory
12	5 y.	M	3 m.	Millard	-	Buckling, splaying of alar cartilage. Widened of alar base.	Open tip rhinoplasty	Oedema	Satisfactory
13	2 y.	M	3 m.	Tennison	-	Buckling of the alar cartilage. Depressed nasal tip. Short columella.	Open tip rhinoplasty v-y plasty	-	Satisfactory
14	12 y.	F	8 m.	Millard	-	Buckling of the alar cartilage. Depressed nasal tip. Short columella.	Open tip rhinoplasty v-y plasty	-	Fair
15	6 y.	F	12 m.	Tennison	-	Buckling, splaying of alar cartilage with classic notching. Widened of alar base.	Open tip rhinoplasty	-	Satisfactory
16	5 y.	M	6 m.	Millard	-	Buckling of the alar cartilage. Widened of alar base. Alar webbing.	Open tip rhinoplasty z-plasty	Oedema	Satisfactory
17	8 y.	F	6 m.	Millard	Disturbed vermillion line	Widened alar base. Alar webbing.	z-plasty	-	Satisfactory
18	6 y.	M	9 m.	Tennison	-	Buckling, splaying of alar cartilage with classic notching. Widened of alar base. Short and deviated columella.	Open tip rhinoplasty v-y plasty	-	Satisfactory
19	2 y.	M	5 m.	Tennison	-	Buckling, splaying of alar cartilage with classic notching. Widened of alar base.	Open tip rhinoplasty	-	Satisfactory
20	8 y.	F	3 m.	Millard	Hypertrophy of the lip	Buckling, splaying of alar cartilage. Alar webbing.	Open tip rhinoplasty z-plasty	-	Satisfactory

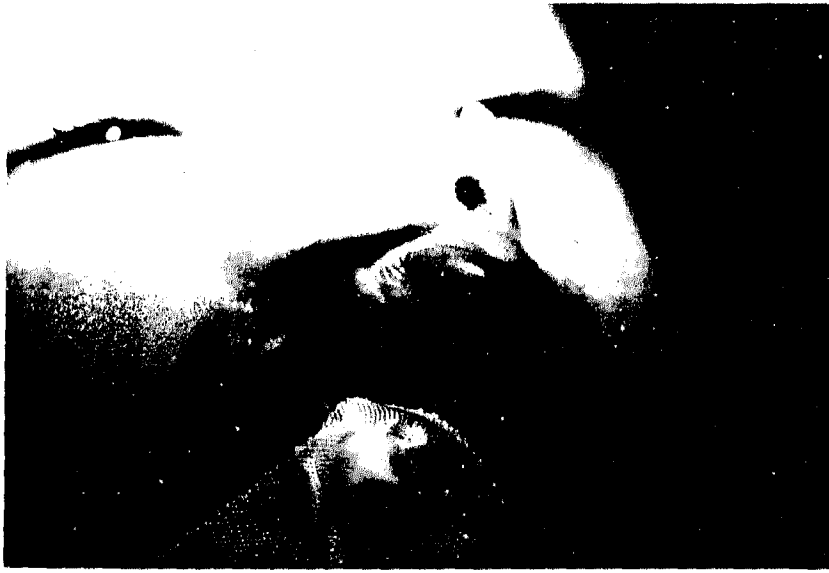

Plate (1) : Preoperative view of male child 6.month with Right unilateral cleft lip:  
Note The nasal deformities (hooding of the alar cartilage, deficient nasal floor,  
deviated columella).



Plate (2) : Intraoperative view of the same child.

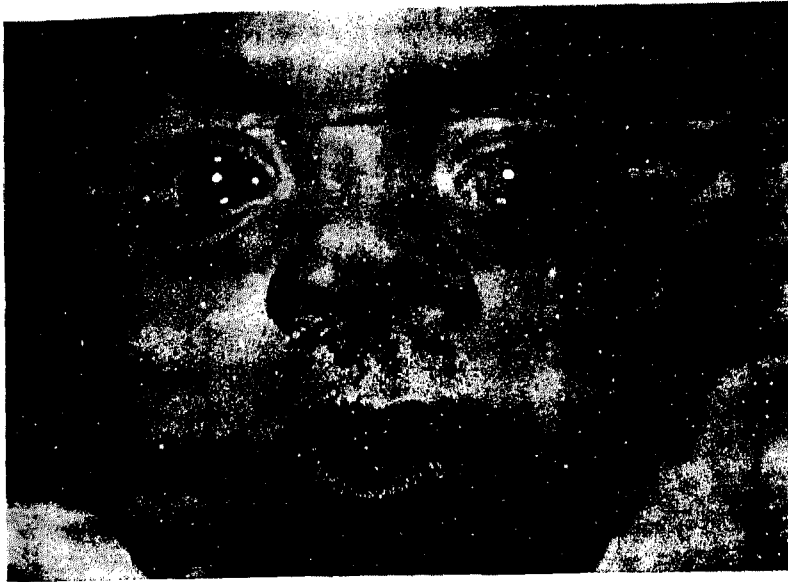

Plate (3) : Post operative view of the same child one week postoperatively.

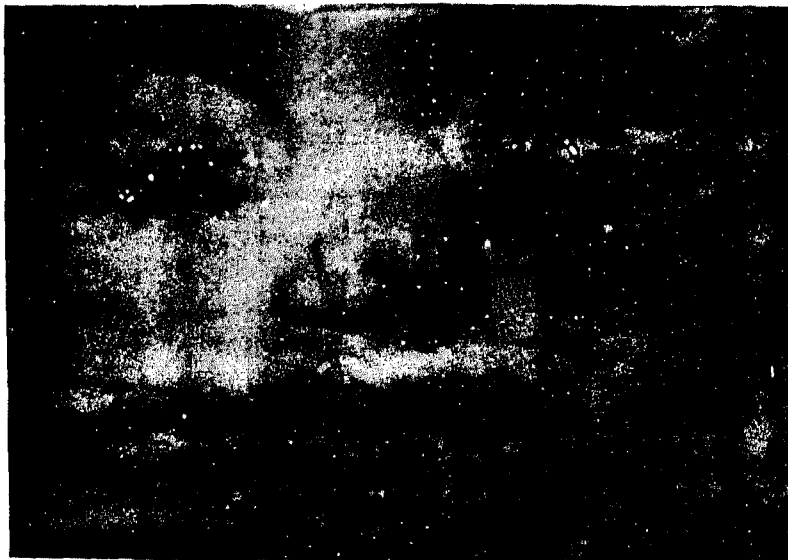

Plate (4) : Preoperative view of a female child 3 years with buckling and bifidity of the alar cartilage.



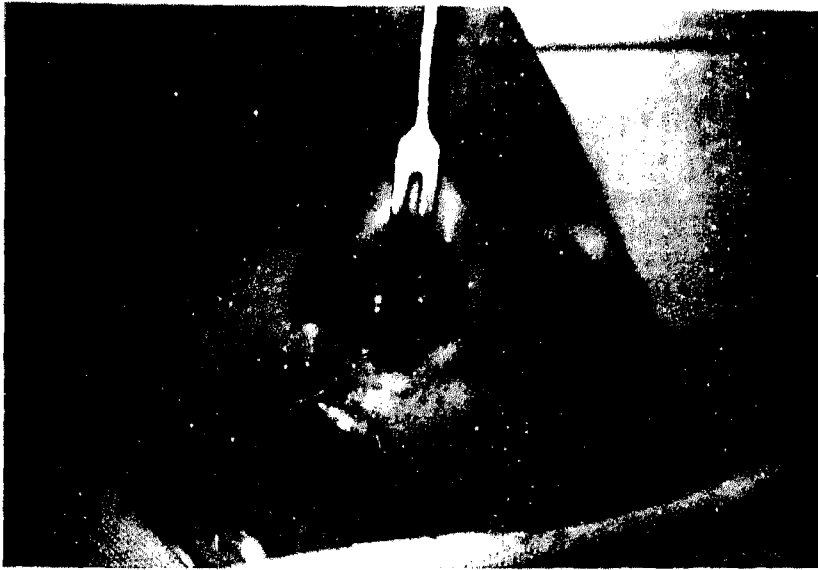


Plate (5) : Intraoperative view of the same child.

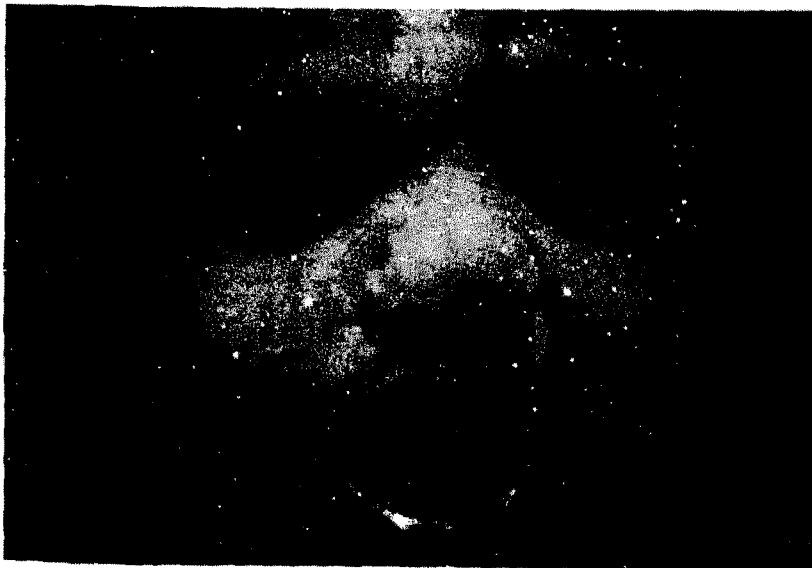

Plate (6) : Postoperative view of the same child one week postoperatively.

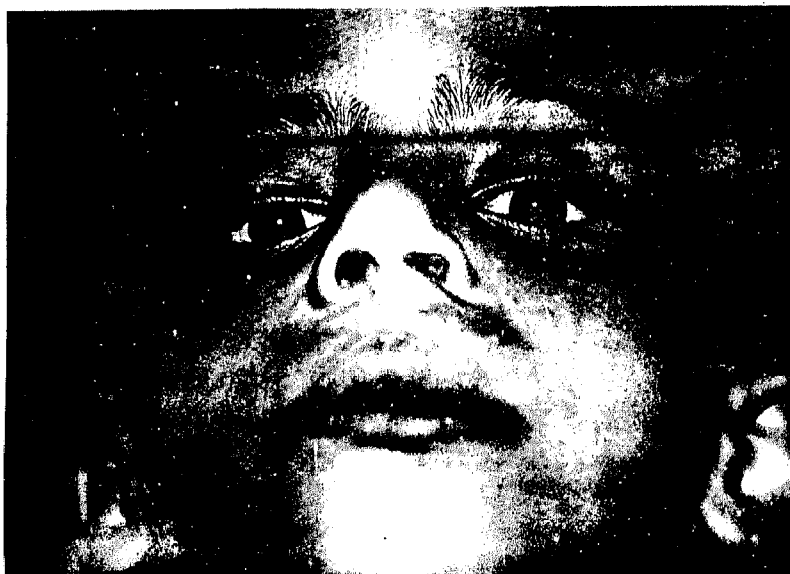

Plate (7) : Preoperative view of a male child 8 years with repaired left unilateral cleft lip with secondary nasal deformity. Note the splaying and inward buckling of the alar cartilages, alar webbing and short deviated columella.

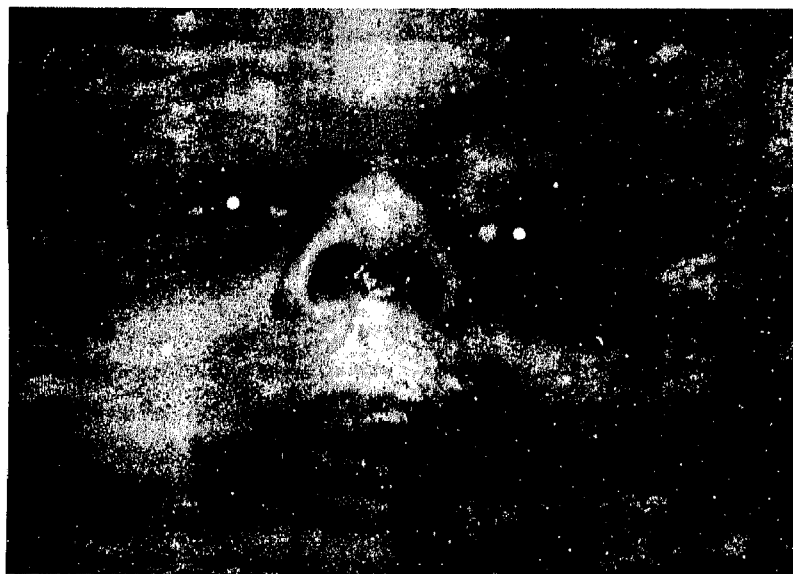

Plate (8) : Postoperative view of the same child. (one week postoperative).

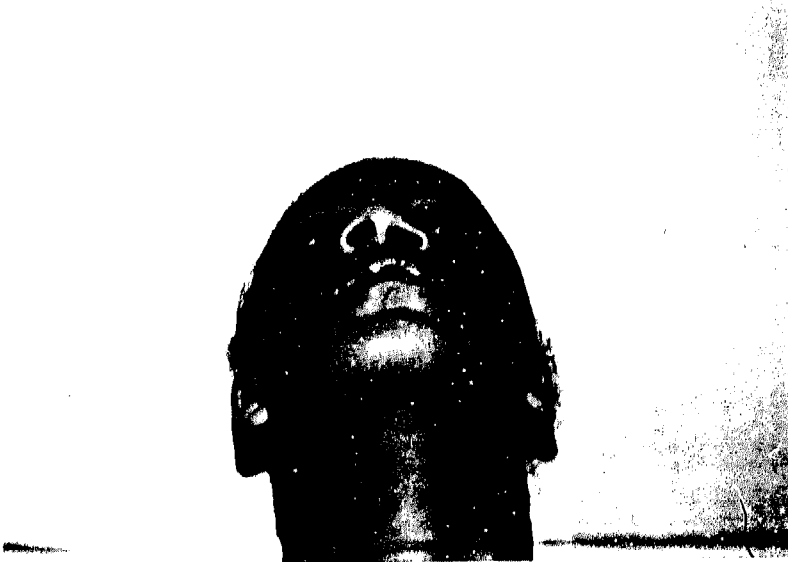

Plate (9) : Preoperative view of female child 12 years with secondary unilateral cleft lip nasal deformity.




Plate (10) : Postoperative view of the same child one week postoperative.

# ***DISCUSSION***

## **DISCUSSION**

The cleft lip nasal deformity remains a surgical challenge despite a multiplicity of approaches to its correction. Consensus regarding selection of an operative procedure, its timing and its effect upon subsequent growth has not been achieved (Kane A.A. et al., 2000).

The management of the cleft lip nasal deformity remains the most difficult, involved, and challenging aspect of cleft lip surgery. The conservative approach of delaying nasal tip surgery until more growth occurred has with stood the test of time, but it is often not accepted by the growth child.

Hence many surgeons now advocate primary rhinoplasty at the time of lip repair, although this does not usually completely correct the problem, it often is successful in reducing the amount of distortion. There is sufficient evidence that it does not interfere with nasal growth and it may lessen the burden of deformity in the growing and developing child (La Rossa D. and Randall P., 1997).

Many authorities agree that early correction of the nose in unilateral cleft lip patient during the preschool year is indicated (Jackson L.T. and Fasching M.C., 1990).

Social pressures at the age of 4 to 6 years hieghten the patients awareness of the residual nasal deformity and consequently demonds for correction intensity. It has been stated that rhinoplasty can be performed at early ages without disturbing nasal and facial growth (Ortiz-Monasterio F. and Olmedo A., 1981, Millard D.R., 1982 and Salyer K.E., 1986).

**Nishimura Y. and Kumoi T., (1991)** advocated open rhinoplasty for severe cleft lip associated nasal deformity during preschool year.

**Millard, (1982)** states that the alar cartilage adequately developed and can be manipulated at this age.

In our cases the age of the primary cases ranged between 6 to 12 months with mean age of 9 months, the age of secondary cases ranged between 2 to 12 years with mean age of 7 years.

In our cases, we operated upon, 5 patients with unilateral cleft lip with marked nasal deformities in the form of hooding and splayed alar cartilage, flattened nasal tip and deviated columella to the non cleft side.

We repaired both the cleft lip and nasal deformity simultaneously.

Fifteen patients with repaired unilateral cleft lip presenting with nasal deformity were operated upon. They were presented with different forms of nasal deformities including alar cartilage deformity in 14 cases, alar webbing in 4 cases, short deviated columella in 4 cases.

**Hoper P.C., (1994)** have been summarized the unilateral cleft lip nasal deformity :

The tip of the nose and caudal septum are deviated from the cleft side; convexity of the septum on the side of the cleft impinging on the airway; the angle of between the medial and lateral crura on the cleft side is excessively obtuse; the dome of the alar cartilage on the cleft side is depressed; the interior of the cleft side nostril from the apex down the cephalic margin of the alar cartilage to the piriform aperture is bowed by linear contracture, the vestibular webbing; the lateral crus is caudally displaced on the cleft side; the cleft side ala buckles inwardly; absent alar facial groove on the cleft side; hypoplastic maxilla on the cleft side; ill

proportioned nares; widened nostril floor on the cleft side; -retrodisplaced medial curs on the cleft side.

Different surgical techniques are described aiming at proper alignment of nasal cartilages.

The open rhinoplasty has many advantages when combined with the repair of cleft lip. It permits mobilization and repositioning of unsacred key elements of the nasal tip under direct vision and also it reshapes the related countours of the upper lip and nostril.

Wide exposure of the entire alar cartilage framework attached with the nasal mucosa achieved by the open rhinoplasty technique, allows movement of the alar cartilage and mucosa as a composite entity. The alar cartilage with attached mucosa moves above while the nasal skin move inferiorly (Thomas C. and Mishra P., 2000).

Trott A. and Mohan N., (1993) used open tip rhinoplasty at the time of the lip repair in the unilateral cleft lip patients, their technique was a modification of Millard, (1964) rotation advancement repair combined with modification of Harashina's Technique, (1990) for secondary correction of the unilateral cleft lip nasal deformity. The result of their technique was satisfactory.

Koh K.S. and Eom J.S., (1998) used an open rhinoplasty with a symmetric incision in the unilateral cleft lip patients for correction of the alar webbing deformity. The principle of their method was that when they lift the nostril with forceps to make the nasal tip symmetric. The alar cartilage of the cleft side is located in the same position as it is to be placed after mobilization and suture suspension and no excessive skin at the

nostril can be observed. This positioning demonstrates that with mobilization of alar cartilage. The external nasal skin become embedded into the nasal cavity. Thus, they could correct the alar webbing deformity simply by an incision and closure. There was no excision of the skin and no transposition of skin flap. Their cases showed that satisfactory results were attainable in the correction of unilateral cleft lip nasal deformity with modification of the incision line for open rhinoplasty.

The principle of our technique was the same in both primary and secondary cases. After elevation of the nostril border with forceps, a bilateral "reverse u" incision connected with v shaped columellar incision was done. After the entire cartilaginous framework of the nose was exposed, suture suspension of the deformed alar cartilage to both ipsilateral and contralateral upper lateral cartilage together with a single interdomal stitch. This was correct the alar cartilage deformities such as flaring, splaying and inward buckling (bifidity) of the alar cartilage also it raised the dome of the nose.

After the skin was redraped there was in 4 cases alar base webbing deformity still present, we did an alar base advancement by adding a z-plasty at the lateral end of the incision (Done after **Koh K.S. and Eom J.S., 1998**).

Complications of our technique were minor early complication such as primary haemorrhage (1 case) and mild oedema (5 cases) which resolve sponaneously and late complication (post traumatic dehiscence) in one case in which the hooding and splaying of the alar cartilage become marked and scheduled for revisional surgery after 6 months insult.



The commonest deformity encountered was the alar cartilage splaying and hooding (95%) of cases to lower extent, alar base webbing deformity encountered in (20%) of cases and columellar deformity was encountered in (20%).

It was found that skeletonization of the alar cartilage by suspension to ipsilateral and contralateral cartilage was effective to correct the hooding and splaying of the alar cartilage together with interdomal stitch elevated the depressed nasal tip.

Elongation of the columella was found to be necessary in 20% of cases after repositioning of the alar cartilage we did v-y closure of the columellar flap.

Alar base advancement in 20% of cases was found to be necessary to do z-plasty at the alar base to correct webbing and flaring of the alar base. The alar base is carefully advanced toward the columella to avoid the untoward sequale of stenosis.

Other nasal deformities such as maxillary hypoplasia and septal deformity which require maxillary osteotomy and septoplasty advised to wait until the patient is 14 years of age or older.

## ***CONCLUSION***

## **CONCLUSION**

The goal of cleft nose reconstruction is : asymmetrical, normal appearing nose in harmony with the rest of the face and compatible with the patients' ethnic background additional goals include, of course, improvement in nasal function and patient self-image.

Correction of the nasal deformity in cases of unilateral cleft lip patients attempts to achieve parity between both alar cartilages, achieve near normal nasal mould.

Primary correction of the nasal deformities, it is a meticulous, difficult technique and further follow up is required to judge facial growth and to compare those with repaired primary and secondary cleft lip nasal deformity.

Secondary correction of the cleft lip nasal deformity can be done at preschool age-period, relieving much social problems to child.

Corrections of this deformity require proper evaluation of the patients, status of the deformity and repair each patient individually.

Multiple means of assessing nasal appearance outcome need to be used to validate results.

Further follow up over years is needed for better assessment of the results of the repair of such complex cleft lip nasal deformities and to judge for the best time of intervention.

# ***SUMMARY***

## ***SUMMARY***

Patients born with cleft lip and palate present with a variety of nasal deformities. They are either congenital or iatrogenic. In our study we gave a short account on the embryology of the face, nose, anatomy of the nose, pathological anatomy of cleft lip nose and a great emphasis was placed on the timing of repair of unilateral cleft lip nasal deformity whether primary during the initial lip repair or secondary repair after lip repair had none and whether secondary repair was done during early in the preschool age or in adolescence or in adult age.

Different surgical techniques of the unilateral cleft lip nose repair whether primary or secondary repairs have been reviewed.

Twenty cases with unilateral cleft lip nasal deformity were repaired, 5 patients, we were repaired primarily during lip surgery and 15 patients were repaired secondary. Our approach in both was open-structure rhinoplasty technique using bilateral reverse – u – incision connected with transcolumellar v-shaped incision with suture suspension of lower lateral cartilage, combined with z-plasty at the lateral end of the rim incision for alar web deformity, v-y plasty for short columella according to the deformity present.

The results of our approach was satisfactory in most of patients.

# *REFERENCES*

**REFERENCES**

- Anastassou G.E., Joos U. and Zollner B.** : Evaluation of the results of delayed rhinoplasty in cleft lip and palate patients. Functional and aesthetic implications and factors that affect successful nasal repair. *B. J. Oral. Maxillofac. Surg.*, 36 : 416 – 24, 1998.
- Anderl H.** : Simultaneous repair of lip and nose in the unilateral cleft (a long-term report). In Jackson, I.T. and Sommerlad, B. (Eds.) : *Recent Advances in plastic surgery. Vol. 3.* Edinburgh, Churchill Livingstone, p. 1, 1985.
- Armstrong G.T., Burk R.W. 3<sup>rd</sup>, Griffing D.W. and Howard P.S.** : A modification of the primary nasal correction in the rotation – advancement unilateral cleft lip repair. *Annals of plastic surgery*, 38 : 236 – 45, 1997.
- Avery J.K.** : The nasal capsule in cleft palate. *Anat. Anz.*, 109 : 722, 1961.
- Balck D.W.** : The cleft lip nose deformity – a definitive repair – presented at the annual meeting of the American Association of Plastic Surgeons, Colorado Springs, 1982.
- Bardach J. and Salyer K.E.** : Correction of nasal deformity associated with unilateral cleft lip. In Bardach J. and Salyer K.E. : *Surgical techniques in cleft lip and palate.* Chicago, Year Book Medical Publishers, 1987.
- Bardach J. and Salyer K.E.** : Correction of secondary unilateral cleft lip deformities. In Bardach J. and Salyer K.E. : *Surgical Techniques in cleft lip and palate.* Chicago, Year Book Medical Publishers, 1987a.

- Barsky A.J.** : Principles and practice of plastic surgery. Baltimore, Williams and Wilkins Company, p. 243, 1950.
- Berkeley W.T.** : Correction of secondary cleft lip nasal deformities. *Plast. Reconstr. Surg.*, 44 : 234, 1969.
- Berkeley W.T.** : The cleft lip nose plast. *Reconstr. Surg.*, 23 : 567, 1959.
- Blair V.P.** : Nasal deformities associated with congenital cleft of the lip. *J. A. M. A.*, 84 : 185, 1925.
- Boo-Chai K. and Tange I.** : The isolated cleft lip nose. *Plast. Reconstr. Surg.*, 11 : 28, 1968.
- Broadbent T.R. and Woolf R.M.** : Cleft lip nasal deformity, *Ann. Plast. Surg.*, 12 : 216, 1984.
- Brown J.B. and McDowell F.** : Secondary repair of cleft lips and their nasal deformities. *Ann. Surg.*, 114 : 101, 1941.
- Brown R.F.** : A reappraisal of the cleft lip nose with the report of a case. *Br. J. Plast. Surg.*, 17 : 168, 1964.
- Chait L.A.** : The "C" costal cartilage graft in reconstruction of the unilateral cleft lip nose. *Br. J. plast. Surg.*, 34 : 169, 1981.
- Clark M.P.A., Hunt N. and Hall-Craggs M.** : Function of the nasal muscles in normal subjects assessed by Dynamic MRI and EMG : Its Relevance to rhinoplasty surgery. *Plast. Reconstr. Surg.*, 101 : 1945, 1998.
- Conelly M.V.** : Surgical correction of the nasal tip of the unilateral cleft lip nose: a combined approach. In: Stucker FJ. ed. *Plastic and Reconstructive surgery of head and Neck*. New York.: B.C. Decker, 629-635, 1991.



- Connelly M.V.** : Secondary repair of the cleft lip and nose in pediatric facial plastic and reconstructive surgery, edited by J.D. Smith and R. Bomsted. Raven Press Ltd, New York (15) : 207, 1993.
- Converse J.M.** : The cartilaginous structures of the nose. *Ann. Otol. Rhinol. Laryngo.*, 64 : 220, 1955.
- Converse J.M., Hogan V.M. and Barton F.E.** : Secondary deformities of cleft lip and nose, and cleft palate. In Converse, J.M. (Ed.) : *Reconstructive plastic surgery*. 2<sup>nd</sup> Ed. Philadelphia, W.B. Saunders Company, 1977.
- Cosman B. and Crikelaire G.F.** : The reconstruction of the unilateral cleft lip nasal deformity. *Cleft Palate J.*, 2 : 95, 1965.
- Crikelaire G.F., Ju D.M.C. and Symonds F.C.** : A method for alar plasty in cleft lip nasal deformities. *Plast. Reconstr. Surg.*, 24 : 588, 1959.
- Cronin T.D.** : Lengthening columella by use of skin from nasal floor and alae. *Plast. Reconstr. Surg.*, 21 : 417, 1958.
- Dado D.V.** : Experience with the function cleft repair. *Plast. Reconstr. Surg.*, 86 : 872 – 81, 1990.
- Delaire J.** : Theoretical principles and technique of functional closure of lip and nasal aperture. *J. Maxillofac. Surg.*, 6 : 109, 1978.
- Dibbel D.G.** : A cartilaginous columellar strut in cleft lip rhinoplasties. *Br. J. Plast. Surg.*, 29 : 247, 1976.
- Dibbell D.G.** : Cleft lip nasal reconstruction : Correcting the classic unilateral defect. *Plast. Reconstr. Surg.*, 69 : 264, 1982.
- Erich J.B.** : A technique for correcting a flat nostril in cases of repaired hare lip. *Plast. Reconstr. Surg.*, 12 : 320, 1953.

---

---

**REFERENCES**

---

---

- Firmin F. and Le Pesteur J. :** Reflexions Sur L'auvert cartilagineux nasal. *Ann. Chir. Plast.*, 22 : 1, 1977.
- Fisher D.M. and Mann, R.J.:** A model for the cleft lip nasal deformity plaste: *Reconstr. Surg*: 101 (6): 1448,1998.
- Fogh-Andersen P. :** Inheritance of harelip and cleft palate. Copenhagen, Nyt Nordisk Forlag Arnold Busck, 1942.
- Foman S., Bell J.W. and Syracuse V.R. :** Hare lip-nose revision. *Arch. Otolaryngol.*, 64 : 14, 1956.
- Fraser F.C. :** Etiology of cleft lip and palate. In Grabb, W.C., Rosenstein, S.W., and Bzoch, K.R. (eds.) : *Cleft lip and palate*. Bosten, Little, Brown and Company, 1971.
- Goodman W.S. and Zorn M.L. :** Unilateral cleft lip nose. *J. Otoloryngol.*, 11 : 198, 1982.
- Gorney M. and Falces E. :** Repair of post cleft nasal deformities with gullwing cartilage graft. In Johanson, B. (Eds.) : *Abstracts of the Second International Congress on Cleft Palate*, Copenhagen, 1973.
- Gosain A.F. and Moore F.O. :** Emberyology of the head and neck. In grabb and smith's plastic surgery, fifth edition, edited by S.J. Aston, and C.H.M Thorne. Lippincott-Raven publishers, Philadelphia, 19 : 223-36, 1997.
- Griesman B. :** Muscles and cartilages -of the nose from the standpoint of a typical rhinoplasty. *Arch. Otolaryngol.*, 39 : 453, 1944.

- Gross C.W. and Boyle T.R.** : Nasal surgery for congenital and acquired diseases, in pediatric facial plastic and reconstructive surgery, edited by J.D. Smith and R. Bomsted. Raven, Press Ltd, New York. (3) : 31, 1993.
- Gubish W.** : The Triple wing Flap Technique to correct the asymmetry of unilateral cleft lip nasal deformities. Scandinavian Journal of plastic & reconstructive surgery and hand surgery 32 (3). 287-94. Sept 1998.
- Hajnisova M.** : Growth of the nose and mouth in children of 6 to 18 years of age. In sanvenero – Rosselli, G. and Boggio – Robutti G. (Eds.): Transactions of Fourth International Congress of Plastic and Reconstructive Surgery. Amsterdam, Excerpta, Medica, 1967.
- Harashina T.** : Open reverse-u incision technique for secondary correction of unilateral cleft lip nasal deformity. Br. J. Plast. Surg., 43 : 557, 1990.
- Hobar P.C.** : Cleft lip II : Secondary Deformities. In F.E. Barton, Jr. (Ed.). Selected Readings in plastic surgery, Vol. 7, No. 22, 1994.
- Hogan V.M. and Converse J.M.** : Secondary deformities of unilateral cleft lip and nose. In Grabb, W.C., Rosenstein, S.E. and Bzoch K.R. (eds.) : Cleft lip and palate. Boston, Little, Brown and Company, 1971.
- Horswell B.B. and Pospisil O.A.** : Nasal symmetry after primary cleft lip repair. Comparison between Delair cheliorhinoplasty and modified rotation advancement. J Oral Maxillofac Surg., 53 : 1025 – 1030, 1995.
- Huffman W.C. and Lierle D.M.** : Studies on the pathologic anatomy of the unilateral harelip nose. Plast. Reconstr. Surg., 4 : 225, 1949.

---

---

*REFERENCES*

---

---

- Hugo N.E. and Tumbusch W.T.** : Repair of unilateral cleft lip nasal deformities. *Cleft Palate J.*, 8 : 257, 1971.
- Humby G.** : The nostril in secondary hare lip. *Lancet*, 1 : 1275, 1938.
- Hurwitz D.J.** : Unilateral cleft lip-nose repair, in Bardach J., Morris H. (eds). *Multidisciplinary management of cleft lip and palate*. Philadelphia, P.A., Saunders, p. 204 – 216, 1990.
- Jackson I.T.** : Commentary on evaluation of open rhinoplasty, by Adamson P.A. et al. *Plastic Surgery Outlook*, 4 : 4, 1990.
- Jackson I.T.** : Suture removal in babies following cleft lip repair (Letter). *Chir. Plast.*, 7, 297, 1984.
- Jackson L.T. and Fasching M.C.** : Secondary deformities of cleft lip, nose and palate in plastic surgery, vol. 4, Philadelphia P.A., Saunders, p. 2771 – 2877, 1990.
- Johnston M.C., Hassell J.R. and Brown K.S.** : The embryology of cleft lip and palate. *Clin. Plast. Surg.*, 2 : 195, 1975.
- Kane, A.A., Pilgram, T.K., Moshiri, M. and Marsh, J.L.** : Long Term outcome of cleft lip Nasal Reconstruction in childhood. *Plast. Reconstr. Surg.*, 105: 1600, 2000.
- Kazanjian V.H.** : Secondary deformities in cleft palate patients. *Ann. Surg.*, 109 : 442, 1939.
- Kernahan D.A., Bauer B.S. and Harris G.D.** : Experience with the Tajima procedure in primary and secondary repair in unilateral cleft lip nasal deformity. *Plast. Reconstr. Surg.*, 66 : 46, 1980.
- Kissel, Andre J.M. and Jacquier** : *The neurocristopathies*, New York, Masson, 1981.

- Koh K.S. and Eom J.S.** : Asymmetric incision for open rhinoplasty in cleft lip nasal deformity. *Plast. Reconstr. Surg.*, 103 : 1835, 1999.
- Krause C.J., Manget D.S. and Pastorek N.** : *Aesthetic facial surgery*. 1<sup>st</sup> ed., Philadelphia : Lippincott, pp. 9 – 12, 1991.
- La Rossa D. and Donath G.** : Primary nasoplasty in unilateral and bilateral cleft nasal deformity. *Clin. Plast. Surg.*, 20 : 781, 1993.
- Lamont E.S.** : Reparative surgery of cleft of cleft lip and nasal deformities. *Surg. Gynecol. Obstet.*, 80: 422, 1945.
- Lanza D.C., Kennedy D.W. and Koltai P.J.** : Applied nasal anatomy and embryology. *Ear Nose Throat. J.*, 70 : 416, 1991.
- LaRossa D.** : Unilateral cleft lip. In *pediatric plastic surgery*. (edited by) Ben2. Michael. Appleton and Lange. Asimon and Schuster Company. p. 47, 1999.
- LaRossa, D. and Randall P.** : Unilateral cleft lip. In *Georgiade plastic, Maxillofacial and Reconstructive Surgery*. Georgiade, G.S., Riefkoh R. and Scottlevin L. (edited, Williams and Wilkins) p. 220, 1997.
- Latham R.A.** : Orthopedic advancement of the cleft maxillary segment. A preliminary report. *Cleft Palate J.*, 17 : 227, 1980.
- Letourneau A. and Daniel R.K.** : The superficial musculoapneurotic system of the nose. *Plast. Reconstr. Surg.*, 82 : 48, 1988.
- Marks K.M., Trevaskis A.E., Berg E.M. and Puchner G.** : Nasal defects associated with cleft lip deformity. *Plast. Reconstr. Surg.*, 34 : 176, 1964.
- Markus A.F. and Detaire J.** : Functional primary closure of cleft lip. *Br. J. Oral Maxillofac. Surg.*, 31 : 281, 1993.

---

---

*REFERENCES*

---

---

- Marsh J.L.** : When is enough enough ? Secondary surgery for cleft lip and palate patients. *Clin. Plast. Surg.*, 17 : 37 – 47, 1990.
- Matthews D.** : The nose tip. *Br. J. Plast. Surg.*, 21 : 153, 1968.
- Mazzola R.F.** : Secondary unilateral cleft lip nose. External approach, *Facial plastic surgery*, 12 : 367 – 78, 1996.
- McCarthy J.G. and Wood-Smith D.** : Phinoplasty. In *plastic Surgery*, Vol. 3. Philadelphia, P.A., Saunders, (35) : 1785, 1990.
- McCollough E.G. and English J.L.** : A new twist in nasal tip surgery. *Arch. Otolaryng*, 111 : 824 – 529, 1985.
- McComb H.** : Primary correction of unilateral cleft lip nasal deformity. A 10-year review. *Plast. Reconstr. Surg.*, 75 : 791, 1985.
- McComb H.** : Primary repair of the bilateral cleft lip nose : A 10-year review. *Plast. Reconstr. Surg.*, 77 : 701, 1986.
- McIndoe A.H. and Rees T.D.** : Synchronous repair of secondary deformities in cleft lip and nose. *Plast. Reconstr. Surg.*, 24 : 150, 1959.
- Millard D.R.** : *Cleft Craft : The evaluation of its surgery*. Vol. 1. Boston, Little Brown and Company. P. 355 – 362, 1976.
- Millard D.R. Jr.** : Composite lip flaps and grafts in secondary cleft deformities. *B. J. Plast. Surg.*, 17 : 22, 1964 (b).
- Millard D.R. Jr.** : Earlier correction of the unilateral cleft lip nose. *Plast. Reconstr. Surg.*, 70 : 64, 1982.

- Millard D.R. Jr.** : Primary correction of the cleft deformity with emphasis on the nose. In proceedings of the x-congress of the international confederation for plastic and reconstructive surgery, Madrid, Spain, June 28 Through July 4, 1992.
- Millard D.R. Jr.** : The unilateral cleft lip nose. *Plast. Reconstr. Surg.*, 34 : 159, 1964.
- Millard D.R., Jr.** : Embryonic rationale for the primary correction of classical congenital clefts of the lip and palate : Hunterian Lecture. *Ann. R. Coll. Surg. Engl.*, 76 : 150, 1994.
- Millard D.R.Jr.** : A Rhinoplasty Tetralogy. Boston : Little, Brown, p. 144, 1996.
- Millard D.R.Jr.** : Cleft craft. Vol. I : The unilateral deformity. Boston, Little, Brown and Company, 1976.
- Millard R.D.Jr. and Morovic C.G.** : Primary unilateral cleft nose correction : A 10-year follow up. *Plast. Reconstr. Surg.*, 102 : 1331, 1998.
- Millard, D.R. Jr. and Latham R.A.** : Improved primary surgical and dental treatment of cleft. *Plast. Reconstr. Surg.*, 86 : 856, 1990.
- Moore K.L.** : The bronchial apparatus and the head and neck. In K.L. Moore (ed.). *The developing Human* (4<sup>th</sup> ed.). Philadelphia : Saunders, 190, 1988.
- Morel – Fatio D. and Lalardrie J.** : External nasal approach in the correction of major morphologic sequelae of the cleft lip nose. *Plast. Reconstr. Srug.*, 38 : 116, 1966.

- Musgrave R.H. and Dupertuis S.M.** : Revision of the unilateral cleft lip nostril. *Plast. Reconstr. Surg.*, 25 : 223, 1960.
- Nakajima T and Yoshimura Y.** : Secondary repair of unilateral cleft lip nose deformity with bilateral reverse-u access incision. *Br. J. Plast. Surg.*, 51 : 176 – 80, 1998.
- Nakajima T., Yoshimura Y. and Kami T.** : Refinement of the “reverse-u” incision for repair of cleft lip nose deformity. *Br. J. Plast. Surg.*, 39 : 345, 1986.
- Natvig P., Sether L.A. Gingrass R.P. and Gardner W.D.** : Anatomical delatis of the osseous cartilaginous framework of the nose. *Plast. Reconstr. Surg.*, 48 : 528, 1971.
- Nishimura Y. and Kumoi T.** : External septorhinoplasty in cleft lip nose. *Ann. Plast. Surg.*, 26 : 526, 1991.
- O'Connor G.B., McGregor M.W. and Tolleth H.** : The management of nasal deformities associated with cleft lips. *Med. Surg.*, 73 : 279, 1965.
- Ogino Y. and Ishida H.** : Secondary repair of the cleft lip nose, *Ann. Plast. Surg.*, 4 : 469, 1980.
- Onizuka T, Itoh, Y and Nakamura, K.** : Procedures for repair of the cleft lip nose. *Aesth. Plast. Surg.*, 7 : 179-185, 1983.
- Onizuka T.** : Repair of columellar base deformity in unilateral cleft lip. *Br. J. Plast. Surg.*, 25: 33, 1972.
- Ortiz – Monasterio F. and Olmedo A.** : Corrective rhinoplasty before puberty : A long-term follow-up. *Plast. Reconstr. Surg.*, 68 : 381, 1981.



- Patton B.M.** : Embryology of palate and the maxillary region. In Grabb, W.C., Rosenstein, S.W. and Bzoch, K.R. (Eds) : Cleft lip and palate. Boston, Little, Brown and Company, 1971.
- Pigott R.W. and Millard D.R. Jr.** : Correction of the bilateral cleft lip nasal deformity. In Grabb W.C., Rosenstein, S.W., and Bzoch, K.R. (Eds.): Cleft lip and palate. Boston, Little, Brown and Company, p. 325, 1971.
- Pollet J.** : Three autogenous struts for nasal tip support. *Plast. Reconstr. Surg.*, 49 : 527, 1972.
- Potter J.** : Some nasal tip deformities due to alar cartilage abnormalities. *Plast. Reconstr. Surg.*, 13 : 358, 1954.
- Rees T.D., Guy C.L. and Converse J.M.** : Repair of the cleft lip nose : Addendum to the synchronous technique with full thickness skin grafting of the nasal vestibule. *Plast. Reconstr. Surg.*, 37 : 47, 1966.
- Reynolds J.R. and Horton C.E.** : An alar lift in cleft lip rhinoplasty. *Plast. Reconstr. Surg.*, 35 : 377, 1965.
- Rifley W. and Thaller S.R.** : The residual cleft lip nasal deformity : An anatomic approach. *Clin. Plast. Surg.*, 23 : 87, 1996.
- Rohrich, R.J. and Tebbets J.B.** : Cleft lip II : Secondary cleft lip / nasal/ alveolar defects. *Selected Readings in plastic surgery*, Vol. 4, No. 22, 1987.
- Salyer K.E.** : Early and Late Treatment of unilateral cleft nasal deformity. *Cleft palate craniofac. J.* 29: 556, 1992.

- Salyer K.E.** : Primary correction of the nasal deformity associated with cleft lip. In M. Cohen, *Mastery of plastic and reconstructive surgery*. New York : Little, Brown, pp. 581 – 594, 1994.
- Salyer K.E.** : Primary correction of the unilateral cleft lip nose, 15-year experience. *Plast. Reconstr. Surg.*, 77 : 558, 1986.
- Schwenzer N.** : Correction of noses associated with clefts of lip and palate. *J. Maxillo. Fac. Surg.*, 1 : 91, 1973.
- Sheen J.H.** : *Aesthetic rhinoplasty*. St. Louis, C.V. Mosby Company, 1978.
- Sheen J.H.** : Middle crus : The missing link in alar cartilage anatomy. *Percept. Plast. Surg.*, 5 : 31, 1991.
- Sheen J.H.** : **Rhinoplasty** : Personal Evaluation and Milestones. *Plast. Reconstr. Surg.*, 105 : 1847, 2000.
- Shendel S.A., Pearl R.M. and DeArmond S.J.** : Pathophysiology of cleft lip muscles following the Initial Surgical Repair. *Plast. Reconstr. Surg.*, 88 : 197, 1991.
- Spira M., Hardy S.B. and Gerow F.J.** : Correction of nasal deformities accompanying unilateral cleft lip. *Cleft palate J.*, 7 : 112, 1970.
- Stark R.B. and Kaplan J.M.** : Development of the cleft lip nose. *Plastic Reconstr. Surg.*, 51 : 413, 1973.
- Stenstrom S.J. and Oberg T.R.H.** : The nasal deformity in unilateral cleft lip. *Plast. Reconstr. Surg.*, 28 : 295, 1961.
- Stenstrom S.J. and Thilander B.L.** : Cleft lip nasal, deformity in the absence of cleft lip. *Plast. Reconstr. Surg.*, 35 : 160, 1965.

- Tajima S.** : The importance of the musculus nasalis and the cure of the cleft margin flap in repair of the complete unilateral cleft lip. *J. Maxillo Fac. Surg.*, 11 : 64, 1983.
- Tajima S. and Maruyama M.** : Reverse-U incision for secondary repair of cleft lip nose. *Plast. Reconstr. Surg.*, 60 : 256, 1977.
- Takato T., Yonehara Y. and Susami T.** : Early correction of the nose in unilateral cleft lip patients using an open method : A 10-year. Review. *J. Oral. Maxillofac. Surg.*, 53 : 28 – 33, 1995.
- Tessier P., Delbet J.P., Pastoriza F. and Aiaich R.** : Séquelles labiales et nasales du bec-de-Liévre complet, chez L'adolescent. Relations avec les malformations et déformations du maxillaire. *Ann, Chir, Plast.*, 14 : 312, 1969.
- Thomas C. and Mishra P.** : Open tip rhinoplasty along with the repair of cleft lip in cleft lip and palate cases. *Br. J. Plast. Surg.*, 53 : 1 – 6, 2000.
- Thomson H.G.** : The residual unilateral cleft lip nasal deformity : A three-phase correction technique. *Plast. Reconstr. Surg.*, 76 : 36, 1985.
- Trauner R.** : Operationen bei Lippen-Kiefer – Gaumen. Spalten in chirurgische operationslehre von B. Breitner. Vol. I, Vienna, Urban and Schwarzenberg, 1956.
- Trott J.A. and Mohan N.** : A preliminary report on open tip rhinoplasty at the time of lip repair in unilateral cleft lip and palate : The alor setar experience. *Br. J. Plast. Surg.*, 46 : 363, 1993.
- Uchida J.** : A new approach to the correction of cleft lip nasal deformities *plast. Reconstr. Surg.*, 47 : 454, 1971.

---

---

*REFERENCES*

---

---

- Uhm K.I, Hwang, S.H. and Choi, B.G.:** Cleft lip nose correction with onlay calvarial bone graft and suture suspension in oriental patients. *Plast. Reconstr. Surg.*, 105 (2): 499, 2000.
- Van Lunteren E., Haxhiu M.A. and Cherniack N.S. :** Respiratory changes in nasal muscle length. *J. Appl. Physiol.*, 59 : 453, 1985.
- Velazquez and Ortiz-Monasterio :** Primary simultaneous correction of the lip and nose in unilateral cleft lip. *Plast. Reconstr. Surg.*, 54 : 558, 1974.
- Vetter U., Pirsig W. and Heinze E. :** Growth activity in human septal cartilage : Age-dependent incorporation of labeled sulfate in different anatomic locations. *Plast. Reconstr. Surg.*, 71 : 167, 1983.
- Vog T. :** Tip rhinoplastic operations using a transverse columellar incision. *Aesthetic Plast. Surg.*, 7 : 13, 1983.
- Whitlow D.R and Constable, J.D. :** Crossed alar wing procedure for correction of late deformity in the unilateral cleft lip nose. *Plast. Reconstr. Surg.* 52: 58, 1973.
- Zide B.M. :** Nasal anatomy : The muscles and tip sensation. *Aesth. Plast. Surg.*, 9 : 193, 1985.

# *ARABIC SUMMARY*

## إصلاح عيوب الأنف في حالات الشفة الأرنبية الأحادية

تتضمن هذه الدراسة نبذة مختصرة عند مراحل تخليق الأنف والوجه ونبذة عن الأنف من الناحية التشريحية ثم نبذة مختصرة عن عيوب الأنف المصاحبة لحالات الشفة الأرنبية ودراسة أنسب الأعمار لإجراء إصلاح هذه العيوب والطرق الجراحية التي استخدمت لإصلاح هذه العيوب وتم إجراء دراسة عملية علي عدد ٢٠ حالة تم تقسيمهم إلي مجموعتين .

**المجموعة الأولى :** وتتضمن ٥ حالات تتراوح أعمارهم بين ٦ و ١٢ شهر وتم إجراء إصلاح عيوب الأنف أثناء إصلاح الشفة الأرنبية .

**المجموعة الثانية :** وتتضمن ١٥ حالة وتتراوح أعمارهم بين ٢ و ١٢ سنة وتم إجراء إصلاح الأنف بعد إجراء إصلاح الشفة الأرنبية ثم عمل دراسة تحليلية للطريقة الجراحية المستخدمة ونتائجها مقارنة بالنتائج السابقة المستخدمة . وكانت النتيجة مرضية في معظم الحالات .

# إصلاح عيوب الأنف في حالات الشفة الأرنبية

رسالة مقدمة  
توطئة للحصول على درجة الماجستير  
في الجراحة العامة

من الطبيب/ مصطفى بدر إبراهيم الصريدي

تحت إشراف  
أ.د. مجدى محمد البربرى

أستاذ جراحة الأطفال  
كلية الطب - جامعة القاهرة

د. ناصر على عبد العال

أستاذ مساعد جراحة الأطفال  
كلية الطب - جامعة القاهرة

د. عمر محمد منصور

مدرس جراحة الأطفال  
كلية الطب - جامعة القاهرة

كلية الطب  
جامعة القاهرة

٢٠٠١

