

Traumatic Reticulopericarditis in a Saanen Goat

Ahmet AKKOÇ*

Department of Pathology, Faculty of Veterinary Medicine, Uludağ University, 16059 Görükle Bursa - TURKEY

Received: 07.07.2006

Abstract: An unusual case of reticulopericarditis traumatica complicated with pyothorax in a Saanen goat is described. Grossly, ascitic fluid accumulation, pyothorax, disseminated abscesses in the liver, spleen and lung, and severe fibrinopurulent exudation in the pericardial sac were observed. A needle syringe, 6 cm in length, was found within the fibrous tissue extending from the pericardial sac to the diaphragm and the anteroventral part of the reticulum. Microscopically, liver, spleen, and lung sections revealed variably sized abscesses surrounded by a wide zone of fibroblast proliferations and connective tissue capsule. Severe fibrous tissue reaction, accumulation of degenerated polymorph nuclear leucocytes, macrophages, and diffuse fibrin fibres were seen in the pericardial sac and epicardium. Occurrence of reticulopericarditis traumatica in small ruminants, especially in goats, is rare and hence is reported here.

Key Words: Traumatic reticulopericarditis, goat, pyothorax

Bir Saanen Keçisinde Travmatik Reticuloperikarditis

Özet: Bu olguda bir Saanen keçisinde görülen ve piyotoraks ile komplike travmatik perikarditis rapor edilmiştir. Makroskopik bakıda, karında sıvı birikimi, piyotoraks, karaciğer, dalak ve akciğerde abse oluşumları ile birlikte fibrinopurulent perikarditis ve miyokarditis gözlemlendi. Retikulumun ön alt kısmından perikard kesesine uzanan yangısal bağ doku içerisinde ve kalbe saplanmış vaziyette, 6 cm uzunluğunda şırınga iğnesi bulundu. Mikroskopik incelemede, karaciğer, dalak ve akciğer kesitlerinde etrafı bağ doku ile sınırlanmış abse alanları dikkati çekti. Perikard kesesinde ve epikardiyumda çoğunluğunu dejenere nötrofillerin oluşturduğu yangı hücreleri ile birlikte fibrin iplikleri ve bağ doku reaksiyonu görüldü. Kalp dokusuna ait bu iki yapıda gözlenen kalınlaşmanın sebebi olarak da şekillenen patolojik değişiklikler düşünüldü. Küçük ruminantlarda ve özellikle keçilerde travmatik reticuloperikarditis olgularına sınırlı sayıda rastlandığı için vaka rapor edildi.

Anahtar Sözcükler: Travmatik retikuloperikarditis, keçi, piyotoraks

Introduction

Traumatic reticuloperitonitis/pericarditis (RPT) is a commonly occurring disease of the digestive tract of ruminants (1-3). RPT is widely seen in mature dairy cattle, occasionally in beef cattle, and rarely in sheep and goats (1,3-5). It results from injury or perforation of the reticulum by swallowed sharp foreign bodies, such as pieces of wire. The sharp object may penetrate the reticulum, diaphragm, and pericardium, resulting in severe inflammation and eventual death (6,7). As sequelae, multiple abscesses can be seen both in abdominal and thoracic organs (1,2,5). Affections of the

ruminant forestomach due to ingested foreign bodies are the subject of attention almost all over the world and of major economic importance due to severe loss of production.

Case History

In the present case, an unusual reticuloperitonitis and severe pericarditis traumatica was reported in a 1-year-old female goat. The animal was found dead on a private farm and referred to the Pathology Department for necropsy. In anamnesis, no useful information except inappetence was obtained from the owner.

* E-mail: aakkoc@uludag.edu.tr

Results and Discussion

Macroscopically, 150 ml of yellowish ascitic fluid with fibrin clots was observed in the abdominal cavity. The liver and diaphragm contained numerous disseminated, raised, round, variably sized (0.5 to 3 cm) nodules. On cut surface, these nodules contained white to tan caseous material. Similar nodules were observed in multiple locations, including the hepatic and mediastinal lymph nodes, lung, and heart. The capsule of the liver was fully covered with thick fibrin deposits. The thoracic cavity was filled with approximately a litre of whitish to green pus. The pericardium and epicardium were diffusely thickened. Due to the fibrinopurulent exudation (estimated 100 ml), the pericardial sac was greatly enlarged and discoloured. When opened, a focal whitish area (fibrous tissue), 0.2 cm x 2 cm, in the left ventricular wall and deposited fibrin clots in the pericardial sac were observed (Figure). On the left part of the pericardial sac an empty fibrous pouch was found. Severe fibrous adhesions among the pericardial sac, diaphragm, liver lobes and partly reticular wall were noted. A needle

syringe, 6 cm in length, was found within the fibrous tissue extending from the anterioventral part of the reticulum to the diaphragm and pericardial sac. Tissue samples were processed routinely for histopathological examination. Microscopically, liver and lung sections revealed variably sized abscesses surrounded by a wide zone of fibroblast proliferations and connective tissue capsule. Severe fibrous tissue reaction, accumulation of degenerated polymorph nuclear leucocytes, macrophages, and diffuse fibrin fibres were seen in the pericardial sac and epicardium. Local fibrous tissue proliferation with numerous macrophages dominated the inflammation in the reticular wall. In the microbiological examination, pure culture colonies of *Arcanobacterium pyogenes* were recovered from the affected organs and fluid in the thoracic cavity.

An unusual case of reticulopericarditis traumatica (RPT) and its complications in a Saanen goat is reported herein. Cattle commonly ingest foreign objects because they do not discriminate against metal materials in feed and do not completely masticate feed before swallowing

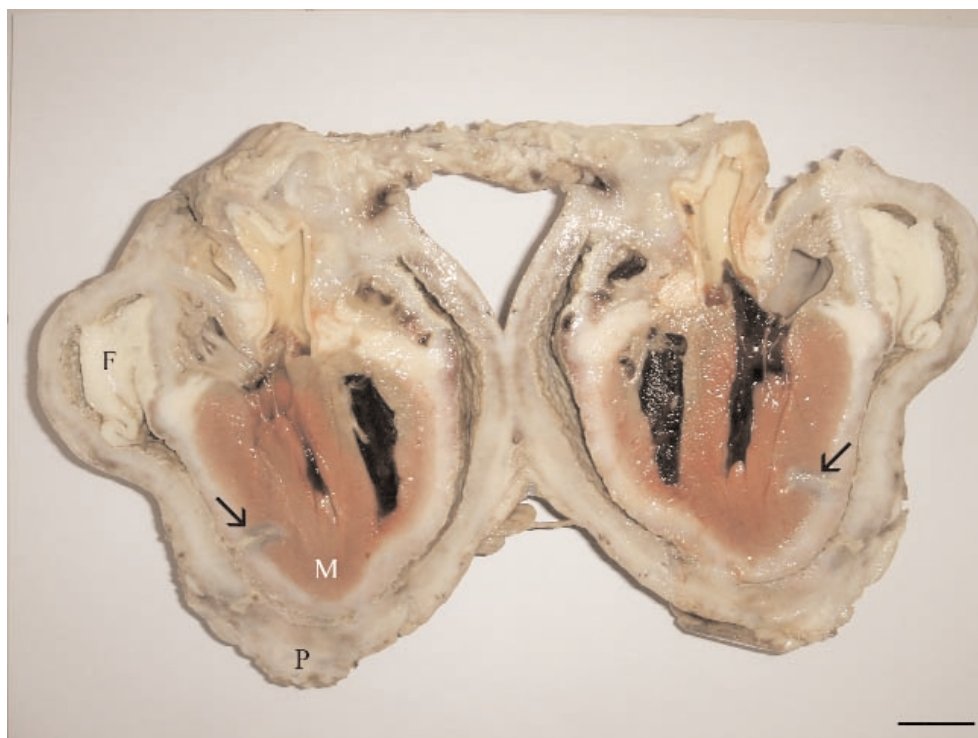


Figure. Heart, pericardium (P), fibrin clot (F), myocardium (M) fibrous reaction in myocardium-penetration point (arrows). Bar = 2 cm.

(1,7). RPT develops as a consequence of perforation of the reticulum by foreign bodies (2-5). Increased intra-abdominal pressure due to pregnancy and ruminal tympany may facilitate the penetration of the foreign body into the reticular wall and other abdominal and thoracic organs. As a complication, suppurative inflammation, characterised by abscess formation in various organs located in the abdominal and thoracic cavity, can be seen (1,5). In the present case, similar abscesses were also found in the liver, diaphragm, heart, and lungs. The primary lesions are located mainly in the heart in RPT. Thickening of the pericardium and epicardium is more common (1,2). The pericardium was also severely affected and its thickness reached 2 cm due to the severe inflammatory changes. Unlike other RPT cases, pyothorax was observed in the goat and it communicated with the empty fibrous abscess pouch on

the left part of the pericardial sac. It is important to differentiate RPT from other diseases marked by stasis of the gastrointestinal tract because it causes similar signs such as ruminal atony and abdominal discomfort. In the reported case, no macroscopic and microscopic findings related with other forestomach diseases were noted. The author thinks that the case is of special significance because goats are dainty in their eating habits and RPT is extremely rare. Although RPT is commonly seen in cattle, practitioners especially interested in small ruminants should be aware of this condition while investigating gastrointestinal problems.

Acknowledgement

The author thanks Dr. Elçin GÜNAYDIN for her kind support.

References

1. Hoffsis, G.F.: Traumatic pericarditis. In: Amstutz H.E., Ed. *Bovine Medicine and Surgery*. 2nd ed., American Veterinary Publishers, Santa Barbara, PA. 1980; 753-756.
2. Sojka, J.E., White, M.R., Widmer, W.R., VanAlstine, W.G.: An unusual case of traumatic pericarditis in a cow. *J. Vet. Diagn. Invest.*, 1990; 2: 139-142.
3. Maddy, K.T.: Traumatic gastritis in sheep and goats. *J. Am. Vet. Med. Assoc.*, 1954; 124: 124-125.
4. Abo-Sheda, M.N., Al-Rawashdeh, O., Al-Natour, M.: Traumatic pericarditis in an Awassi lamb. *Br. Vet. J.*, 1991; 147: 78-81.
5. El-Sebaie, A.: Uncommon sequelae of ingested sharp foreign bodies in goats. I- Traumatic reticuloperitonitis with suppurative hepatitis in a goat. *Ass. Vet. Med. J.*, 1994; 30:158-161.
6. Haque, M.A., Kral, E., Nechvatal, M., Roztocil, V.: Radiocinematology of induced traumatic reticuloperitonitis in goats. *Acta Vet. Bruno.*, 1976; 45:141-148.
7. Braun, U., Gansohr, B., Haessig, M.: Ultrasonographic evaluation of reticular motility in cows after administration of atropine, scopolamine and xylazine. *J. Vet. Med. A. Physiol. Pathol. Clin. Med.*, 2002; 49: 299-302.