

## Case Report

Department of Clinical Sciences, College of Veterinary Medicine, Urmia University, Urmia, Iran

# Congenital Ocular Dermoid Cyst in a River Buffalo (*Bubalus bubalis*) Calf

F. SARRAFZADEH-REZAEI<sup>1,3</sup>, A. A. FARSHID<sup>2</sup> and S. SAIFZADEH<sup>1</sup>

Addresses of authors: Departments of <sup>1</sup>Clinical Sciences; and <sup>2</sup>Pathobiology, College of Veterinary Medicine, PO Box 57155/1177, Urmia University, Urmia, Iran; <sup>3</sup>Corresponding author: Tel.: +98 914 141 1418; fax: +98 441 2777099; E-mail: f.sarrafazadeh@mail.urmia.ac.ir

With 3 figures

Received for publication February 15, 2006

### Summary

Clinical and histopathological findings of a congenital ocular dermoid cyst, located at the lower eyelid of a river female buffalo (*Bubalus bubalis*) calf were presented. A soft, fluctuant, non-tender, hyperaemic cystic mass was detected overlaying the left eye. Fine needle aspirate revealed filamentous debris with no malignant cells. The cyst was treated surgically by orbital exenteration and subsequently subjected to histopathological examination. The histopathological study disclosed a conjunctival dermoid cyst. This report is novel, in that; such ocular cyst has not previously been described in river buffalo calves.

### Introduction

Dermoid cysts are benign tumours that represent the simplest form of teratoma (Perry and Tuthill, 2003). Dermoid cysts are developmental choristomas (an abnormal arrangement of tissues not normally present at the site) and are often evident soon after birth (Abou-Rayyah et al., 2002). They are cysts of developmental origin and histologically characterized with squamous cell lining, keratinoid or mucoid content, occasionally associated with fatty component and calcified structure (Nishie et al., 2003). In humans, the commonest choristomatous cyst of the orbit is dermoid cyst, which is usually lined by keratinizing squamous epithelium (West et al., 1997). The orbital area is one of the most common sites for dermoid cysts (McCullough et al., 1991). Although dermoid cysts are well documented in humans, they have been reported less frequently in the animal species.

Buffalo has been an integral part of livestock agriculture in Asia for over 5000 years producing draft power, milk, meat and hides. Even today, 153 million buffalo provide 73 734 759 t of milk and 3 089 875 t of meat, and in several countries, up to 30% of the draft power for agricultural operations (Nanda and Nakao, 2003). Unfortunately, however, this species did not receive the attention of the policy makers and the researchers in accordance with its merits, which resulted in buffalo population decline in several eastern Asian countries. While the buffaloes are of major importance to the economic and social fabric of several regions in Asia, there are limited reports describing congenital anomalies in the buffaloes.

As judged from the paucity of case reports in the buffalo, it would appear that dermoid cysts have not yet been documen-

ted in the river buffalo, and to our knowledge, this is the first reported case of ocular dermoid cyst in this species.

### Case Presentation

A 2-day-old newborn river female buffalo calf (*Bubalus bubalis*) was admitted for evaluation of a congenital mass overlaying the left eye. On ophthalmic examination, the left eye revealed a soft, fluctuant (fluid filled), non-tender, hyperaemic cystic mass in the lower palpebral conjunctiva, covering the orbit entirely (Fig. 1). No hair growing from the surface was seen. The morbid left globe was apparently smaller than normal in size (microphthalmos). The globe and third eyelid invasion were not noted grossly. A fine needle aspiration was collected from the cystic mass and submitted for cytological examination and culture. The cystic fluid showed filamentous debris with no malignant cells. Routine aerobic bacteriological culture of the content yielded no growth. Vital signs and results of blood examination were within normal ranges. Following discussion with the owner, it was elected to perform an orbital exenteration, regardless of the mass aetiology. Preoperative antibiotic and anti-inflammatory therapy was instigated. The calf was placed in lateral recumbency and the affected eye aseptically prepared. Retrobulbar regional anaesthesia was given (Skarda, 1987). The calf's eyelids were sutured together with no. 2 silk in simple continuous suture pattern, and the suture ends left long. A transpalpebral incision, 1 cm from the eyelid margin, was made around the orbit. Sharp and blunt dissection was performed for 360° around the orbit continuing down to the caudal aspect. All muscles, adipose tissues, the lacrimal glands, and fascia were removed, along with the eyelids and eyeball. When the optic stalk was reached, a pair of right-angled forceps was used to grasp the stalk, which was then severed distally. Closure was performed in the standard fashion.

On gross examination, the cystic mass was pink in colour and measured 2.5 × 3 × 5 cm. When sectioned, the lesion contained colourless transparent fluid, and the cystic cavity and hairs within it were clearly visible.

For histopathological evaluations, tissue sample from the cyst was placed in 10% neutral-buffered formalin, processed routinely; thin sections were cut, and stained with haematoxylin and eosin. Microscopically, the lesion exhibited skin structures, comprising of epidermis, dermis, and skin append-

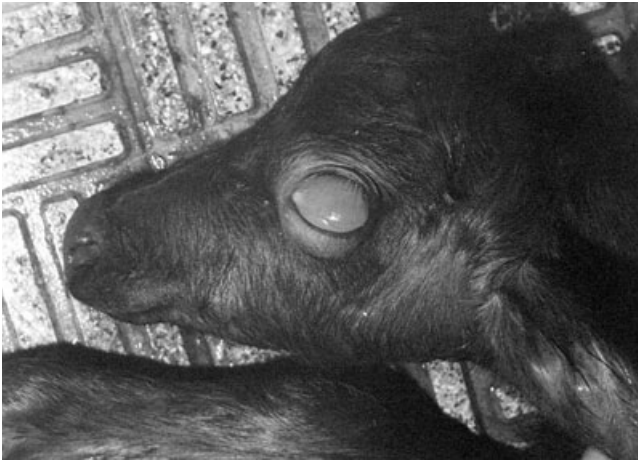

Fig. 1. Gross appearance of dermoid cyst occupied the left orbit of the presented buffalo calf. The mass entirely covers the intraocular structures.

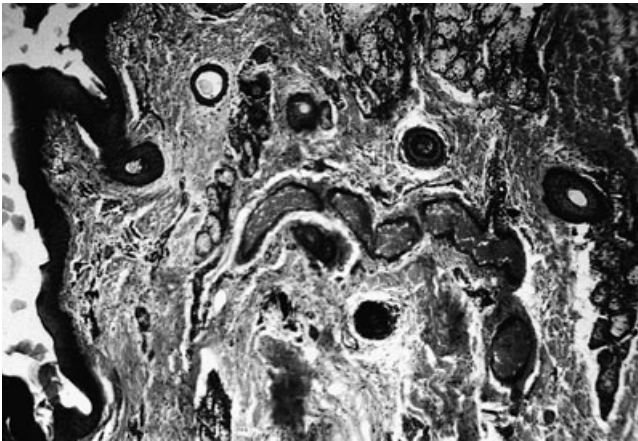


Fig. 2. Dermoid cyst composed of skin structures with congested blood vessels (haematoxylin and eosin,  $\times 40$ ).

ages, i.e. hair follicles, sebaceous and sweat glands (Fig. 2). Some of the sebaceous glands showed both intact and disintegrating sebum-containing secretory cells, in some parts cystic change was also seen (Fig. 3). Muscle fibres were also evident. The blood vessels were found to be congested. The histopathological diagnosis was conjunctival dermoid cyst. Other intraorbital structures, including the globe, were not examined microscopically. The postoperative period was uneventful and no untoward sequel was seen.

### Discussion

We described the clinical and histopathological findings of a congenital ocular dermoid cyst in a newborn river buffalo calf. Dermoid cysts are early developmental lesions that occur because of the sequestration of embryonic epithelium in deeper layers along the fetal lines of closure (Colombo et al., 2000). Dermoid cysts have long been thought of as congenital and benign but it has also been reported as being acquired secondary to traumatic displacement of epithelial tissue (Hillyer et al., 2003). In human, dermoid cysts are thought

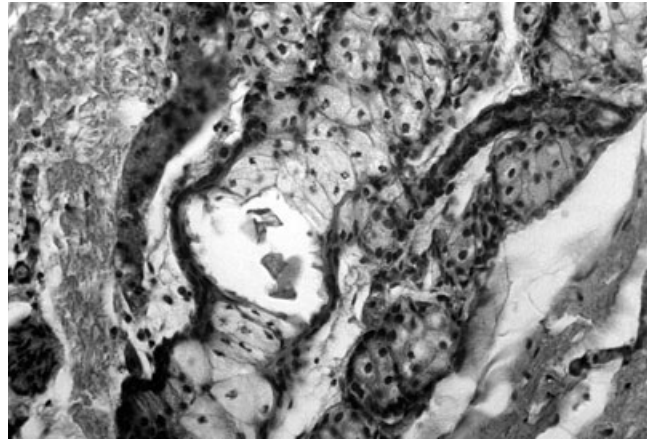


Fig. 3. Sebaceous gland contained intact and disintegrating sebum-containing secretory cells with cystic change (haematoxylin and eosin,  $\times 400$ ).

to arise; at between 3 and 5 weeks of gestation, from an abnormal implantation of surface ectoderm along the embryonic lines of closure that form the facial features (Abou-Rayyah et al., 2002). Heritability of dermoid cysts is thought to occur in Rhodesian ridgeback dogs; the condition is over-represented in this breed and a linkage to one or two pairs of recessive genes is suspected. In horses, no breed disposition is recognised (Hillyer et al., 2003). Being a congenital anomaly, dermoid cyst was recorded in different cattle breeds (Gelatt, 1972; Yeruham et al., 2002). Although, it is believed not to be inherited (Gelatt, 1972), Barkyoumb and Leipold (1984), described the ocular dermoid cyst in Hereford cattle a genetically transmitted defect, in which characteristics of autosomal recessive and polygenic inheritance were observed (Barkyoumb and Leipold, 1984; Howard, 1993; Radostits et al., 2000). The owner of the buffalo calf in this report also owned its sire and of the calves sired by the ox, none had shown any dermatological lesions to his knowledge. To our knowledge, there have been no reported cases of congenital ocular dermoid cyst in the buffalo; nevertheless, its occurrence is recommended to be duly noted in the breeding herds.

Dermoid cysts may be unilateral or bilateral (Radostits et al., 2000), but rarely appear bilaterally, except in certain lines of Hereford cattle (Gelatt, 1991). Dermoid cysts are sometimes associated with microphthalmos (Radostits et al., 2000). Microphthalmos is more frequently the result of the involution of the primary optic vesicle or the abnormal closure of the embryonic cleft in which other ocular anomalies are present, including occasional cysts. Pure microphthalmos (nanophthalmos) occurs rarely, and is the result of an arrested development of the globe in all dimensions after the embryonic fissure has closed. The eye is small without other apparent abnormalities (Gelatt, 1991). Presumably, the presence of unilateral ocular dermoid cyst along with smaller than normal globe (microphthalmos) in the present case is in accordance with the cyst attributes in the cattle. Although there was a clinical diagnosis of microphthalmos in this buffalo calf, but it was not confirmed histopathologically.

Dermoid cysts are uncommon in the horse, with only three reports describing them in the dorsal midline, ventral thorax and distal limbs (Hillyer et al., 2003). There have been single

reports of dermoid cysts in other large animals, including the camel and bull (Purohit et al., 1989; Baird et al., 1993). In contrast, these lesions are well documented in humans, dogs and cats (Hillyer et al., 2003). Dermoid cysts represent the most common space-occupying orbital mass in childhood (Colombo et al., 2000).

The site affected by dermoid cysts varies with the species and even breed. In humans, they have been recorded in the brain (Akhaddar et al., 2002), spinal cord (Nishie et al., 2003), ovary (Ferrari et al., 2003), penis (Hillyer et al., 2003), tongue (Hillyer et al., 2003), orbit (Colombo et al., 2000; Abou-Rayyah et al., 2002; Perry and Tuthill, 2003), nose (Amir and Dunham, 2001), jaw bone (Takeda et al., 2003), neck and rectum (Hillyer et al., 2003), whereas in dogs and cats the brain and spinal cord are most often affected. A single report described a dermoid cyst in the tongue of a German shepherd dog (Liptak et al., 2000). Gelatt (1972), reported a corneoconjunctival dermoid cyst in a 6-month-old male Hereford calf. Hillyer et al., 2003, reported six dermoid cysts along the dorsal midline of a 3-year-old thoroughbred-cross gelding. To the best of our knowledge, excluding ours, no reported cases of dermoid cyst in the conjunctiva have been documented in the buffalo, and this is the first report of its kind.

Depending on the type of the eye tumour, its location, and the equipment available, the tumours may be removed surgically, or by cryotherapy, hyperthermia, or radiofrequency. A combination of these modalities can also be used (Irby, 2004). Some surgical procedures include eyelid wedge resection, third eyelid resection, enucleation, evisceration, or exenteration of the entire globe and orbital contents (Irby, 2004). Although the implications of spillage of the dermoid cyst content are controversial, the standard practice is to avoid the spillage of the cystic content (Ferrari et al., 2003). In the present case, due to the type and location of the tumour, orbital exenteration was selected to eliminate the risk of cystic spillage. Moreover, malignant transformation of the dermoid cysts that reported in the humans (Overton and Crocker, 1997; Ashkan et al., 2002) was of practical importance in considering the ocular exenteration to avoid extra-morbid second operation to the calf.

Histologically, dermoid cysts are similar, in that they are well-circumscribed cystic structures that lie within the dermis. Dermoid cysts are lined by a keratinising stratified squamous epithelium (Colombo et al., 2000). The squamous lining of a dermoid cyst shows the formation of some adnexal structures (Hillyer et al., 2003). Numerous fully mature sebaceous glands, with or without other dermal appendages, are widely scattered in the connective tissue layer of the cyst wall. The presence of sebaceous glands is an indispensable histological element with which to make a diagnosis of dermoid cyst (Takeda et al., 2003). The contents of dermoid cysts are fat with fluid, and hair ball (Tangjitgamol et al., 2003). Soft tissue dermoid cysts usually contain sebaceous glands, hair follicles, hairs, eccrine glands and, in about 20% of cases, apocrine glands (Takeda et al., 2003). In the present case, the dermal appendages found were the hair follicles, sebaceous and sweat glands in which some of the sebaceous glands showed both intact and disintegrating sebum-containing secretory cells, in some parts of these glands, cystic change were also seen.

In conclusion, the surgeons should keep this rare type of tumour in mind when faced with the prospect of ocular masses in the buffalo, especially in neonatal buffalo calves.

## References

- Abou-Rayyah, Y., G. E. Rose, H. Konrad, S. J. Chawla, and I. F. Moseley, 2002: Clinical, radiological and pathological examination of periocular dermoid cysts: evidence of inflammation from an early age. *Eye* **16**, 507–512.
- Akhaddar, A., M. Jiddane, N. Chakir, R. E. Hassani, B. Moustarchid, and F. Bellakhdar, 2002: Cerebellar abscesses secondary to occipital dermoid cyst with dermal sinus: case report. *Surg. Neurol.* **58**, 266–270.
- Amir, R., and M. E. Dunham, 2001: Bilateral choanal atresia associated with nasal dermoid cyst and sinus: a case report and review of the literature. *Int. J. Pediatr. Otorhinolaryngol.* **58**, 81–85.
- Ashkan, K., P. Wilkins, and H. Marsh, 2002: Squamous cell carcinoma: a rare complication of dermoid cysts. *Neuropathol. Appl. Neurobiol.* **28**, 164.
- Baird, A. N., D. F. Wolfe, and A. H. Groth, 1993: Dermoid cyst in a bull. *J. Am. Vet. Med. Assoc.* **202**, 298.
- Barkyoub, S. D., and H. W. Leipold, 1984: Nature and cause of bilateral ocular dermoids in Hereford cattle. *Vet. Pathol.* **21**, 316–324.
- Colombo, F., L. M. Holbach, and G. O. H. Naumann, 2000: Conjunctival cyst and conjunctival dermoid of the orbit. *Orbit* **19**, 13–19.
- Ferrari, M. M., R. Mezzopanea, A. Bulfonia, B. Grijuelaa, R. Carminatib, E. Ferrazzic, and G. Pardia, 2003: Surgical treatment of ovarian dermoid cysts: a comparison between laparoscopic and vaginal removal. *Eur. J. Obstet. Gynecol. Reprod. Biol.* **109**, 88–91.
- Gelatt, K. N., 1972: Corneo-conjunctival dermoid cyst in a calf. *Vet. Med. Small Anim. Clin.* **67**, 1217.
- Gelatt, K. N., 1991: *Veterinary Ophthalmology*, 2nd edn. pp. 240–241, 611, 616. Lea & Febiger, Philadelphia, PA.
- Hillyer, L. I., A. P. Jackson, G. C. Quinn, and M. J. Day, 2003: Epidermal (infundibular) and dermoid cysts in the dorsal midline of a three-year-old thoroughbred-cross gelding. *Vet. Dermatol.* **14**, 205–209.
- Howard, J. L., 1993: *Current Veterinary Therapy III (Food Animal Practice)*. p. 93. W.B. Saunders, Philadelphia, PA.
- Irby, N. L., 2004: Surgical diseases of the eye in farm animals. In: Fubini, S. L., and N. G. Ducharm (eds), *Farm Animal Surgery*, pp. 429–459. Saunders, St Louis, MI.
- Liptak, J. M., P. J. Canfield, and G. B. Hunt, 2000: Dermoid cyst in the tongue of a dog. *Aust. Vet. J.* **78**, 160–161.
- McCullough, M. L., A. T. Glover, W. J. Grabski, and T. G. Berger, 1991: Orbital dermoid cysts showing conjunctival epithelium. *Am. J. Dermatol.* **13**, 611–615.
- Nanda, A. S., and T. Nakao, 2003: Role of buffalo in the socio-economic development of rural Asia: current status and future prospectus. *Anim. Sci. J.* **74**, 443–455.
- Nishie, A., K. Yoshimitsua, H. Hondaa, H. Iriea, H. Aibeaa, and K. Shinozakia, 2003: Presacral dermoid cyst with scanty fat component: usefulness of chemical shift and diffusion-weighted MR imaging. *Comput. Med. Imaging Graph.* **27**, 293–296.
- Overton, C. E., and S. G. Crocker, 1997: Malignant transformation within a dermoid cyst. *J. Obstet. Gynecol.* **17**, 411.
- Perry, J. D., and R. Tuthill, 2003: Simultaneous ipsilateral temporal fossa and orbital dermoid cysts. *Am. J. Ophthalmol.* **135**, 413–415.
- Purohit, N. R., D. S. Chouhan, and P. R. Dudi, 1989: Dermoid cysts in camels. *Br. Vet. J.* **145**, 89–90.
- Radostits, O. M., C. C. Gay, D. C. Blood, and R. W. Hinchcliff, 2000: *Veterinary Medicine*, 9th edn. pp. 595, 599. W.B. Saunders, London.
- Skarda, R. T., 1987: Local and regional analgesia. In: Short, C. E. (ed.), *Principles and Practice of Veterinary Anesthesia*, pp. 109–111. Williams & Wilkins, Baltimore, MD.

- Takeda, Y., Y. Oikawa, M. Satoh, and S. Nakamura, 2003: Latent form of multiple dermoid cysts in the jaw bone. *Pathol. Int.* **53**, 786–789.
- Tangjitgamol, S., S. Manusirivithaya, C. Sheanakul, S. Leelahakorn, T. Thawaramara, and S. Jesadapatarakul, 2003: Squamous cell carcinoma arising from dermoid cyst: case reports and review of literature. *Int. J. Gynecol. Cancer* **13**, 558–563.
- West, J. A., R. H. Drewe, and A. A. McNab, 1997: Atypical choristomatous cysts of the orbit. *Aust. New. J. Ophthalmol.* **25**, 117–123.
- Yeruham, I., S. Perl, and M. Liberboim, 2002: Ocular dermoid in dairy cattle – 12 years survey. *Rev. Med. Vet.* **153**, 91–92.